




SIMFER

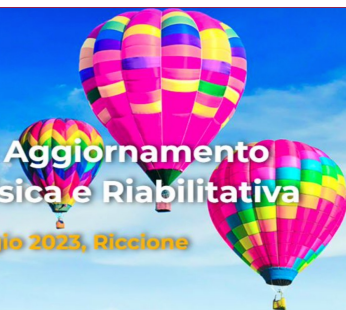SOCIETÀ ITALIANA
DI MEDICINA FISICA
E RIABILITATIVA

The Italian Society
of Physical and
Rehabilitative Medicine



34° Corso di Aggiornamento
Medicina Fisica e Riabilitativa

28-31 Maggio 2023, Riccione



I principali tumori primitivi e secondari del rachide: inquadramento diagnostico e approccio chirurgico

Alessandro Gasbarrini

Chirurgia Vertebrale — Istituto Ortopedico Rizzoli Bologna



A chi di loro mancano tre vertebre?

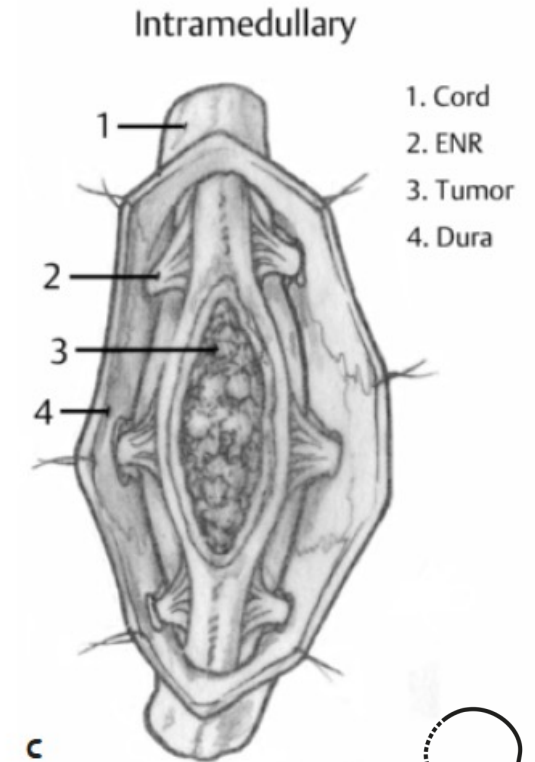
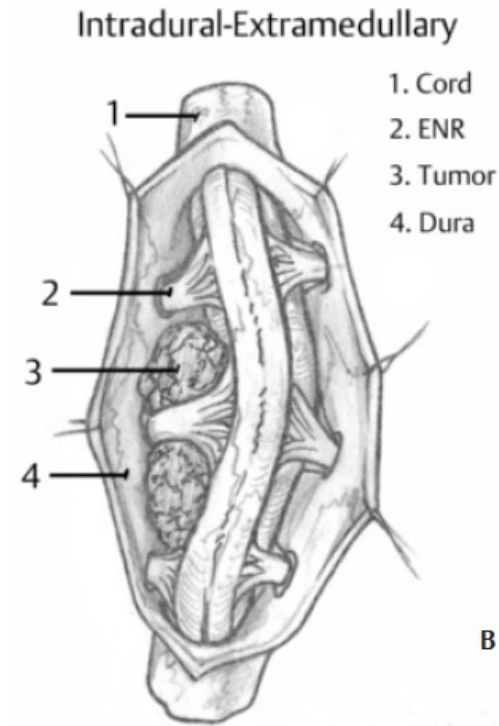
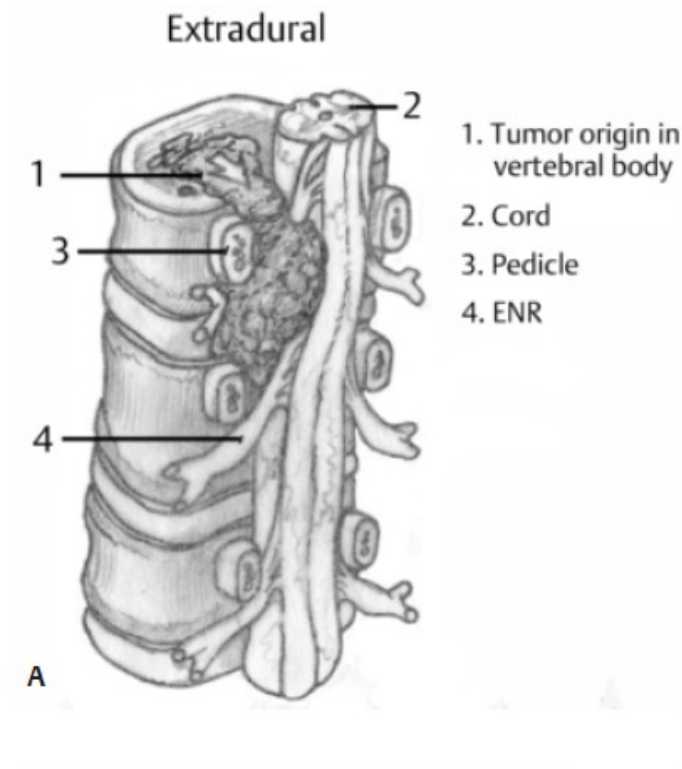
Cortina, 2022



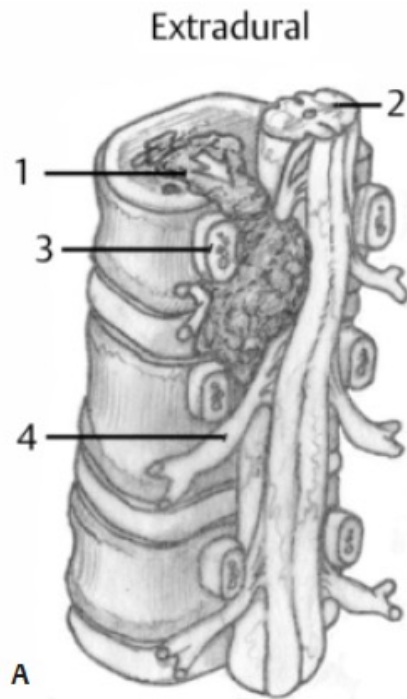
*Stefano, 42 anni,
affetto da sarcoma di Ewing
vertebrale,
tumore maligno dell'osso
e sottoposto ad intervento di
asportazione di tre vertebre e
ricostruzione con impianto protesico*

Cortina, 2022

Tumori della colonna - Epidemiologia



Tumori della colonna - Epidemiologia



1,9 milioni di tumori maligni diagnosticati negli US nel 2020

- Fino al 40% di questi svilupperà metastasi vertebrali
- Il 10-20% di questi ultimi svilupperà compressioni midollari

2900 tumori primitivi maligni dell'osso diagnosticati negli US in un anno

- 10% nella colonna

Tumori della colonna - Epidemiologia

Metastasi

27 – 30 casi/100.000/anno (USA)



Tumori primitivi del rachide

2,5 - 8,5 casi/100.000/anno (USA)



Chi JH, Bydon A, Hsieh P, et al. Epidemiology and demographics for primary vertebral tumors. *Neurosurg Clin N Am.* 2008 Jan;19(1):1-4.

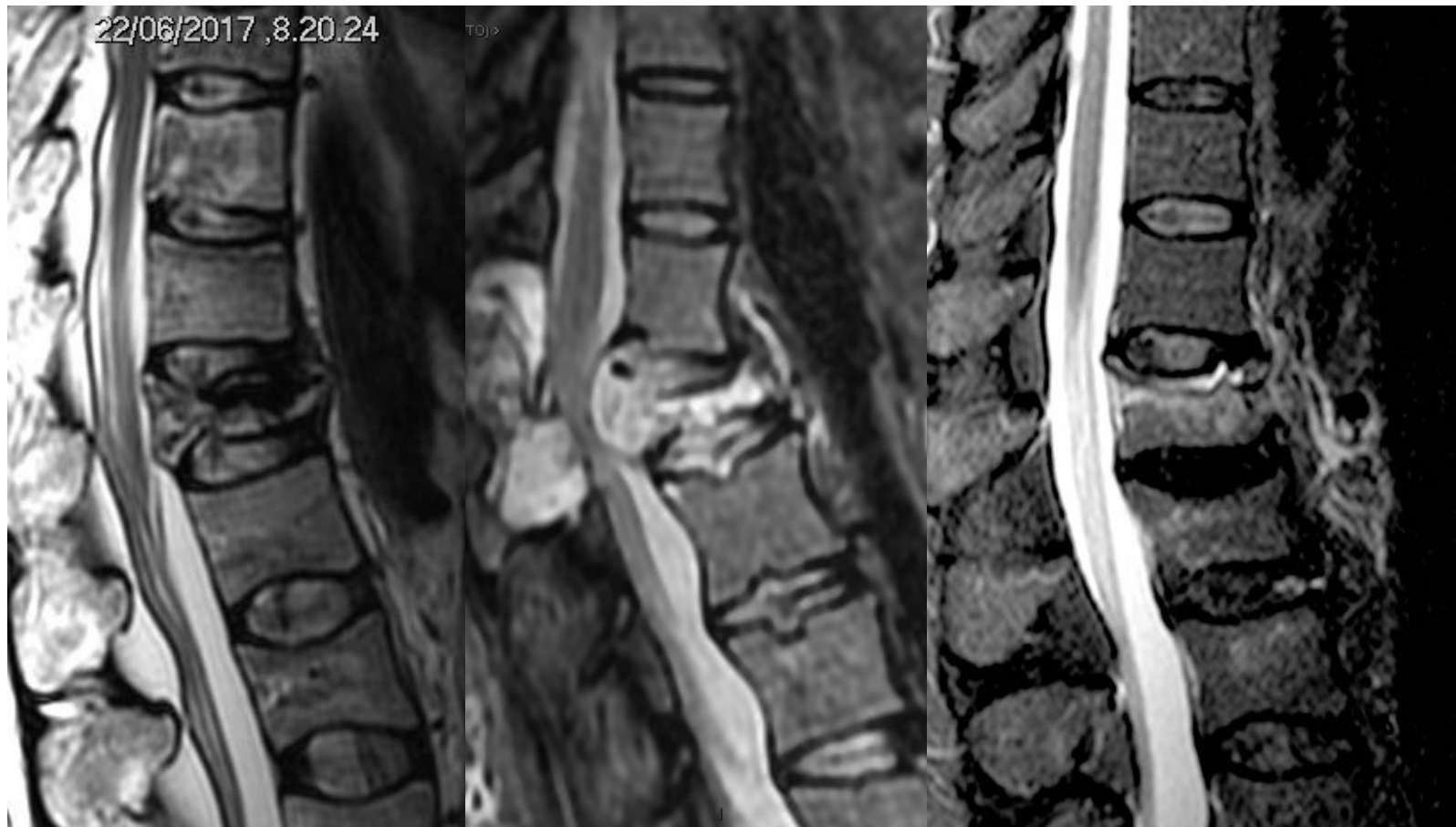Tumori primitivi

Molto meno frequenti delle metastasi

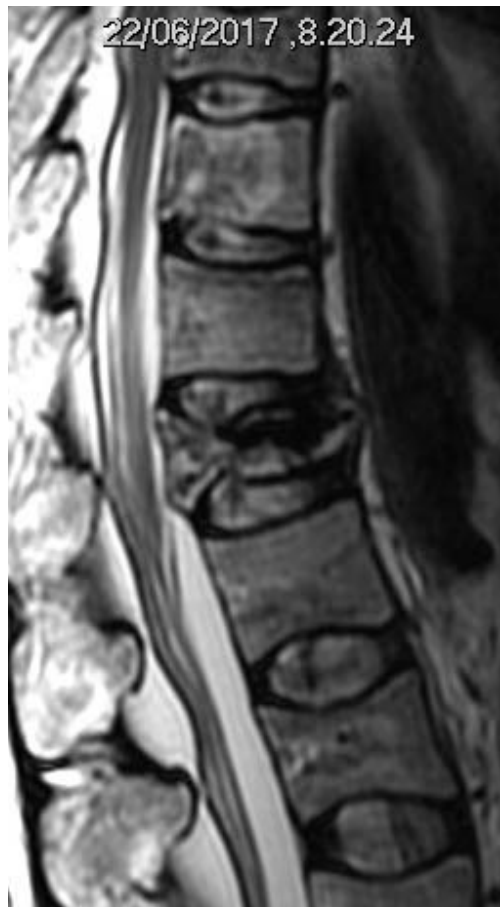Necessitano di trattamenti diversi

Devono essere sospettati

Diagnosi

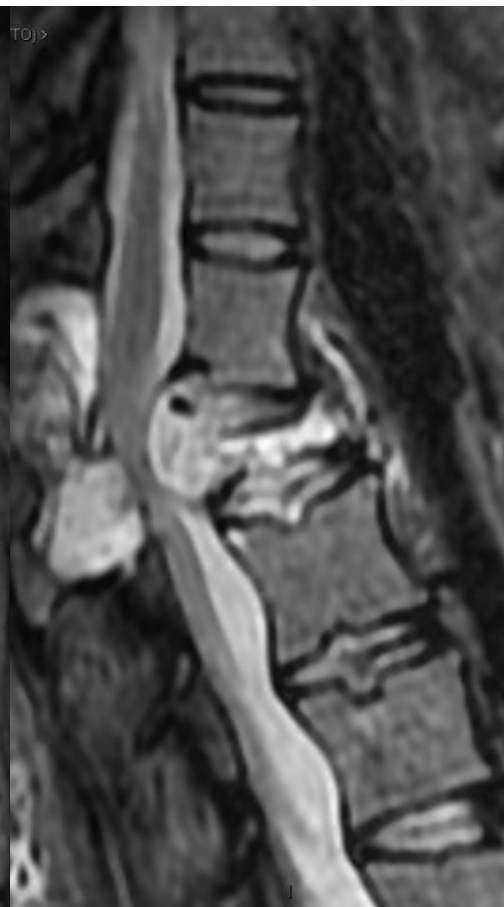

M, 27 aa



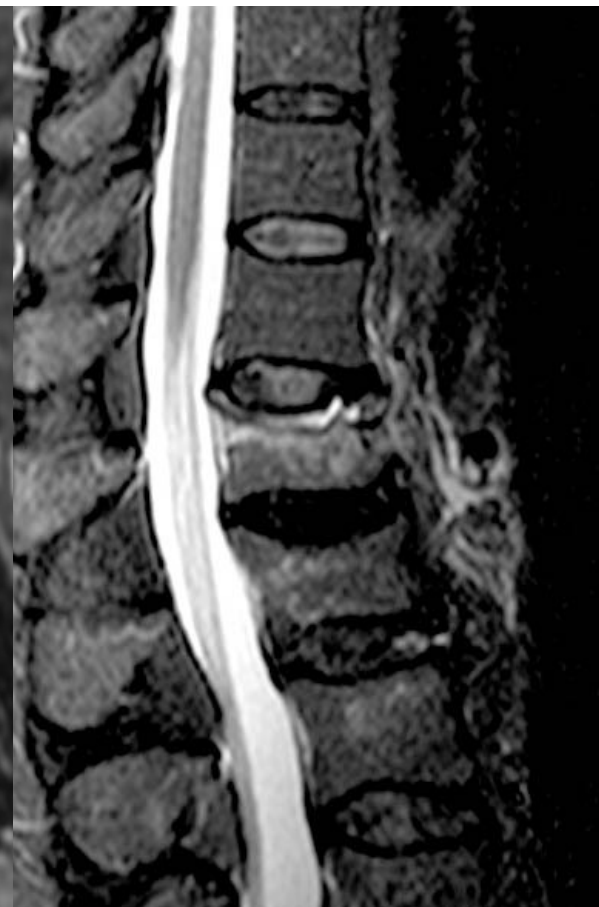Meta "Yolk-sac Tumor"

F, 42 aa



Emangioendotelioma
Epiteliode

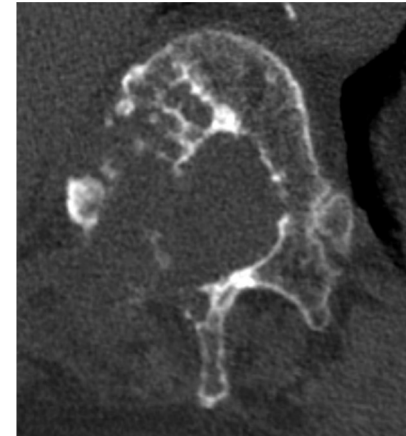
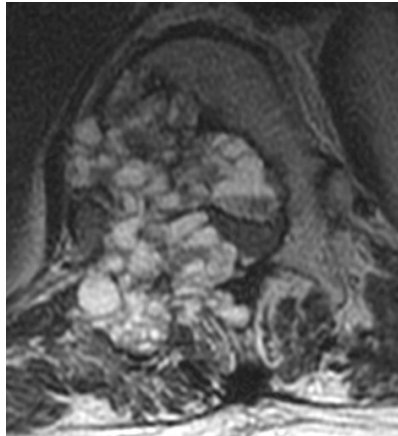
M, 67 aa



Mieloma Multiplo

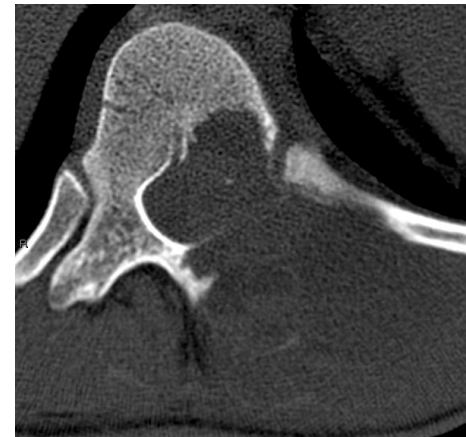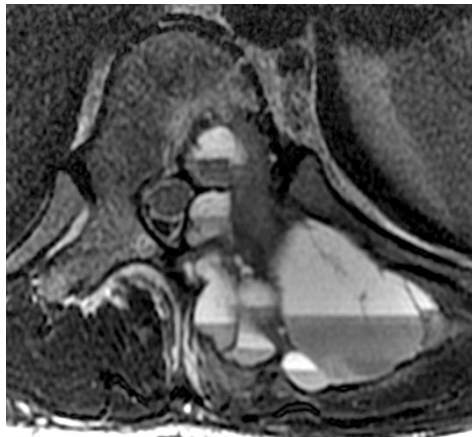
78-year-old
woman,
T12 cystic lesion

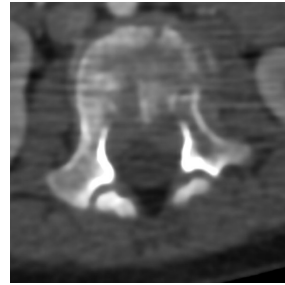
Breast
carcinoma
metastasis



17-year old
boy,
T11 cystic lesion

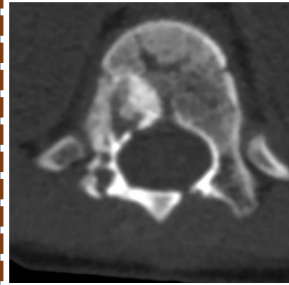
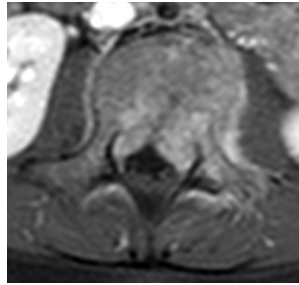
Aneurysmal
bone cyst





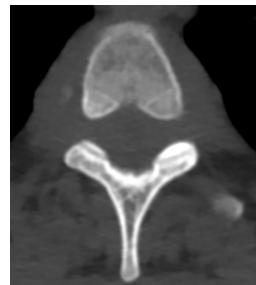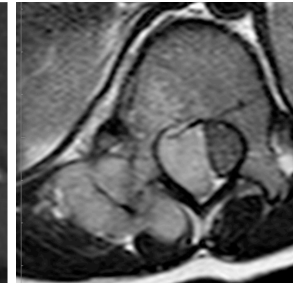
2 1/2-year-old girl

L3 Eosinophilic granuloma



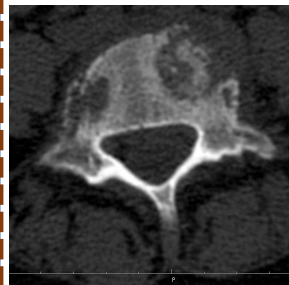
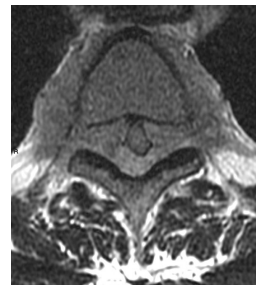
8-year-old boy

T12 Ewing sarcoma



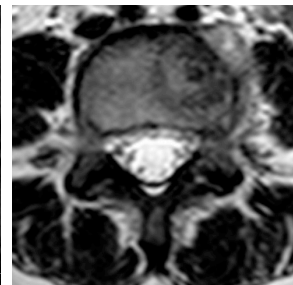
51-year-old man

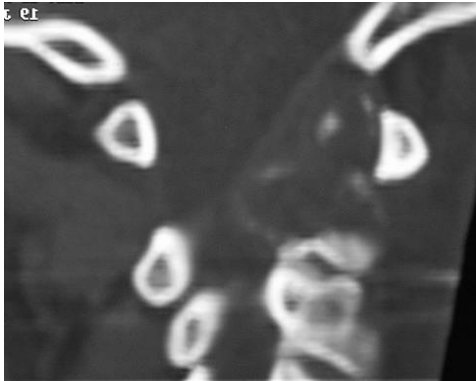
T3 NH follicular lymphoma



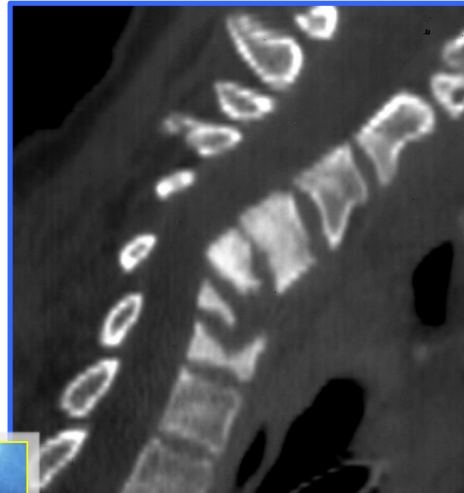
12-year-old girl

L5 TB spondylitis

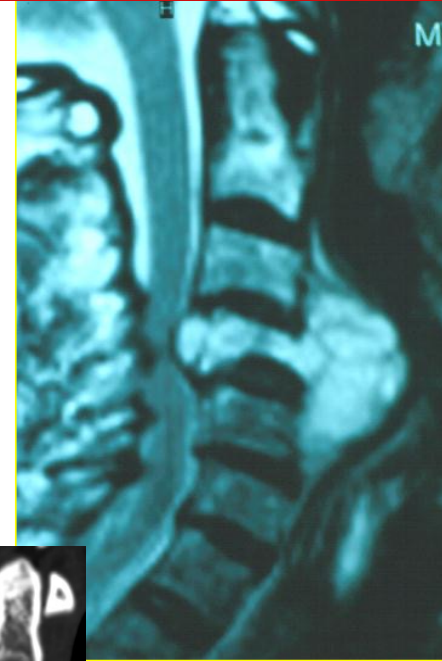




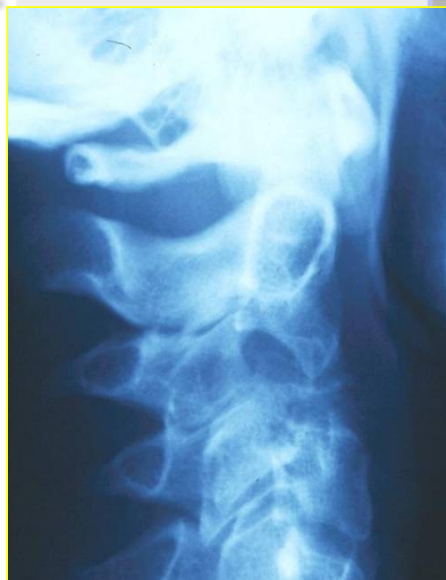OGS C2



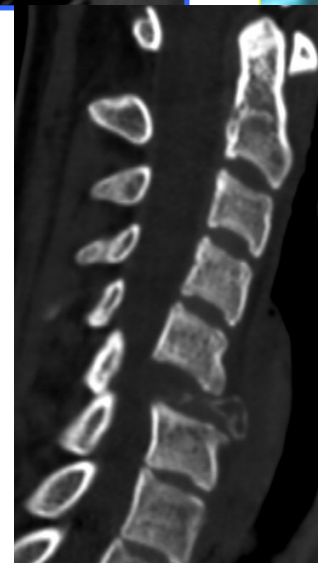Spd C4-C7



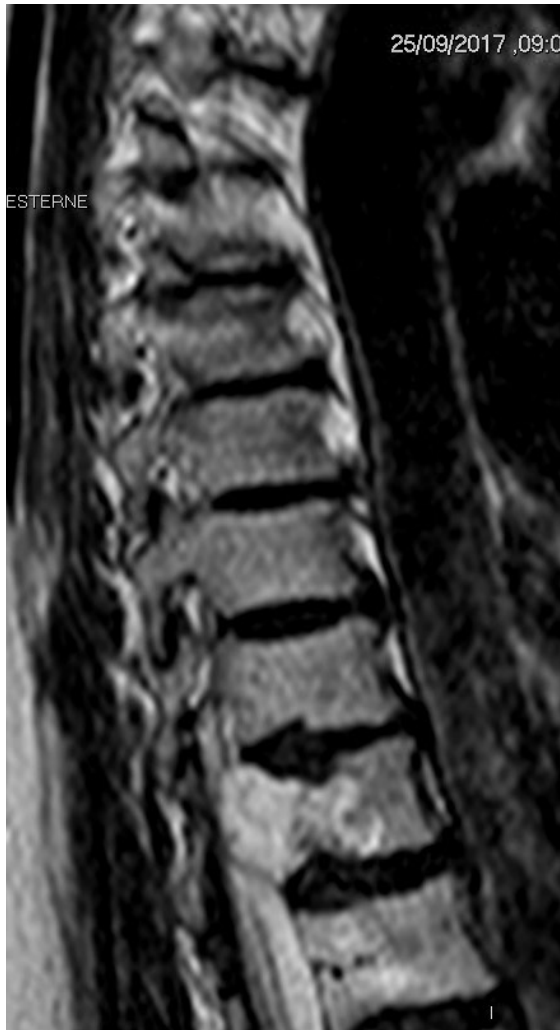Cordoma C4



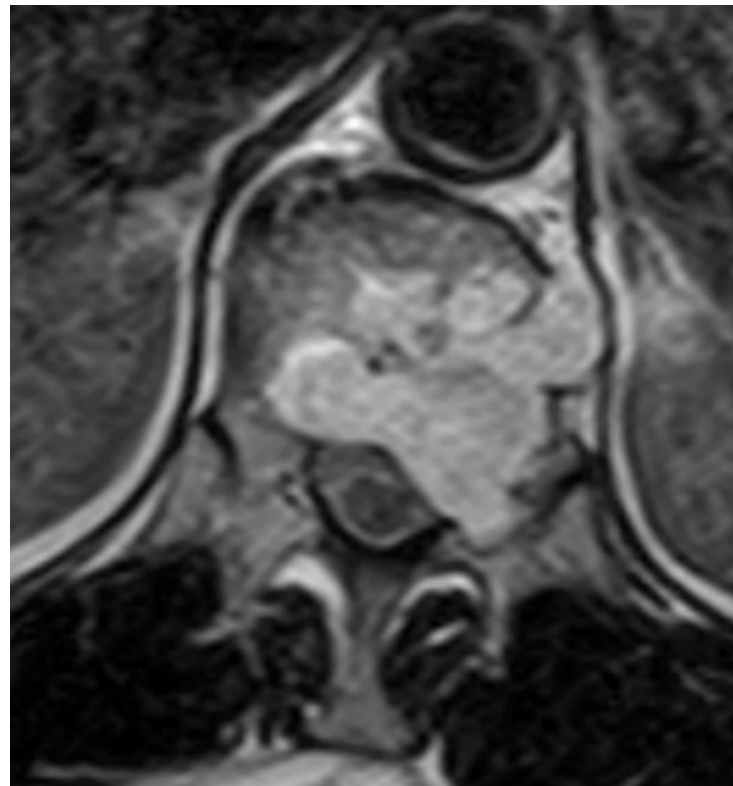
TCG C3



ABC C6



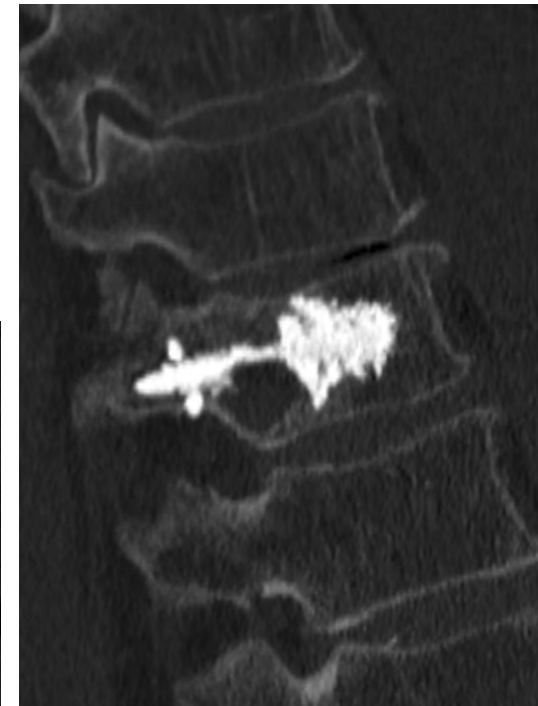
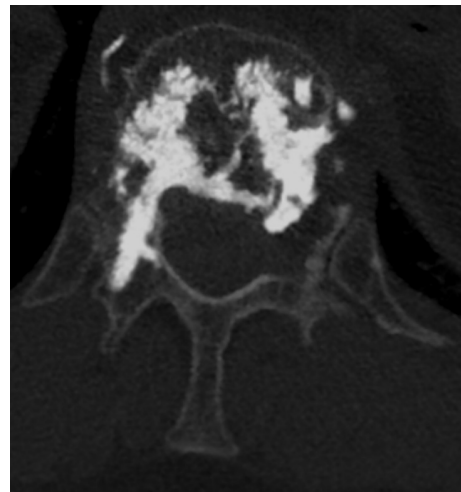
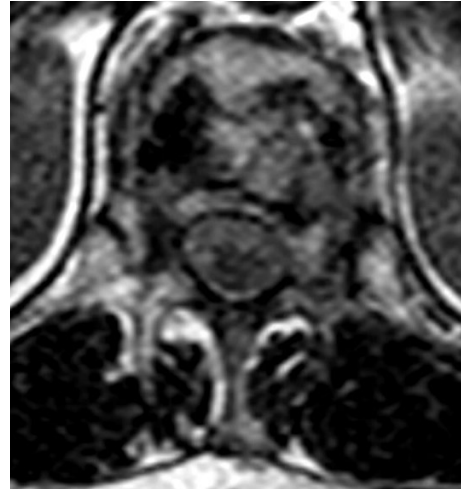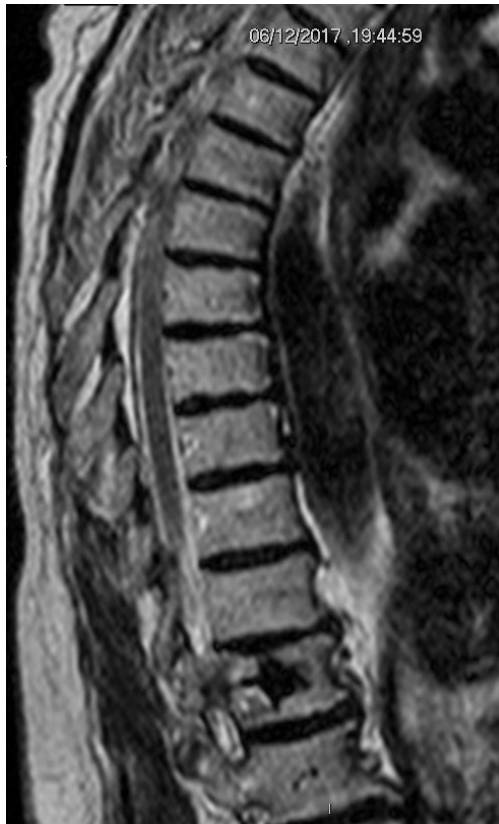D.M.D, F, 60 aa – Frattura Patologica T12



D.M.D, F, 60 aa – Frattura Patologica T12

'Settembre 2017:

- Agobiopsia (non diagnostica)
- Termoablazione
- Vertebroplastica

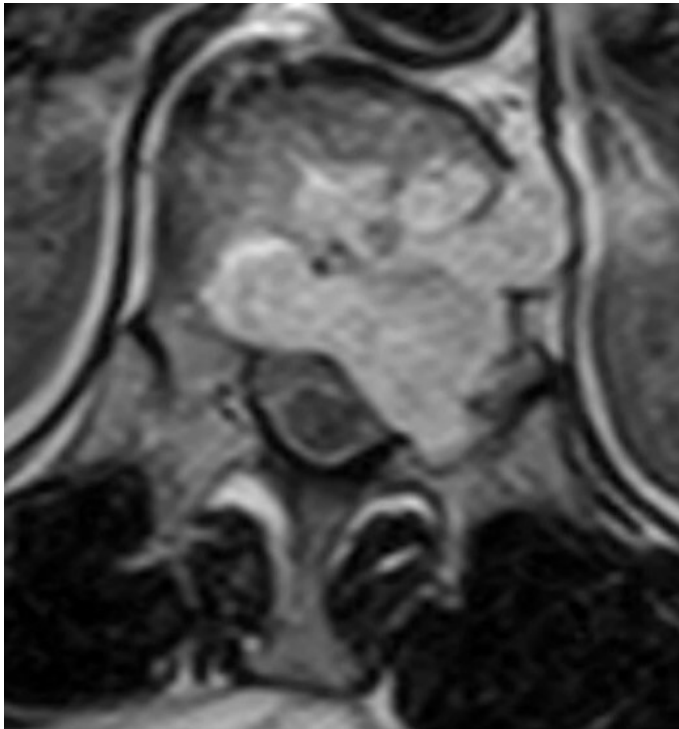


D.M.D, F, 60 aa – Frattura Patologica T12

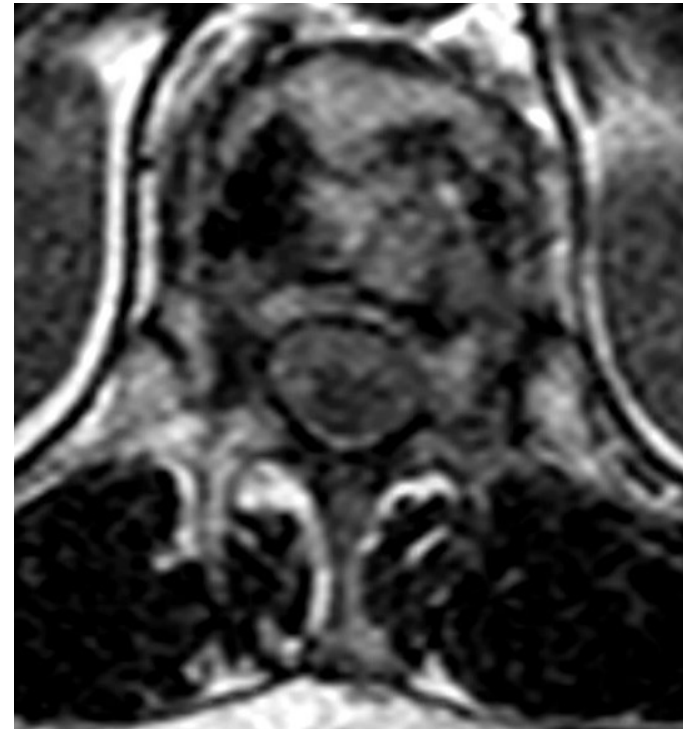'Settembre 2017:

- Agobiopsia (non diagnostica)
- Termoablazione
- Vertebroplastica

Pre



Post



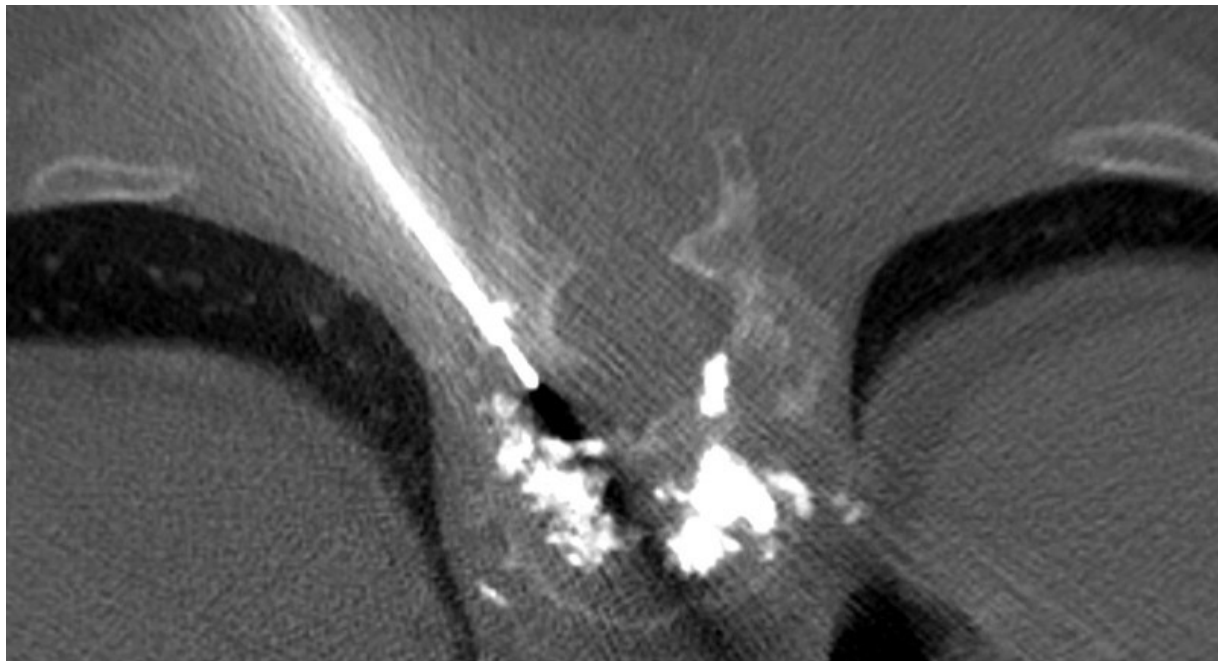
D.M.D, F, 60 aa – Frattura Patologica T12

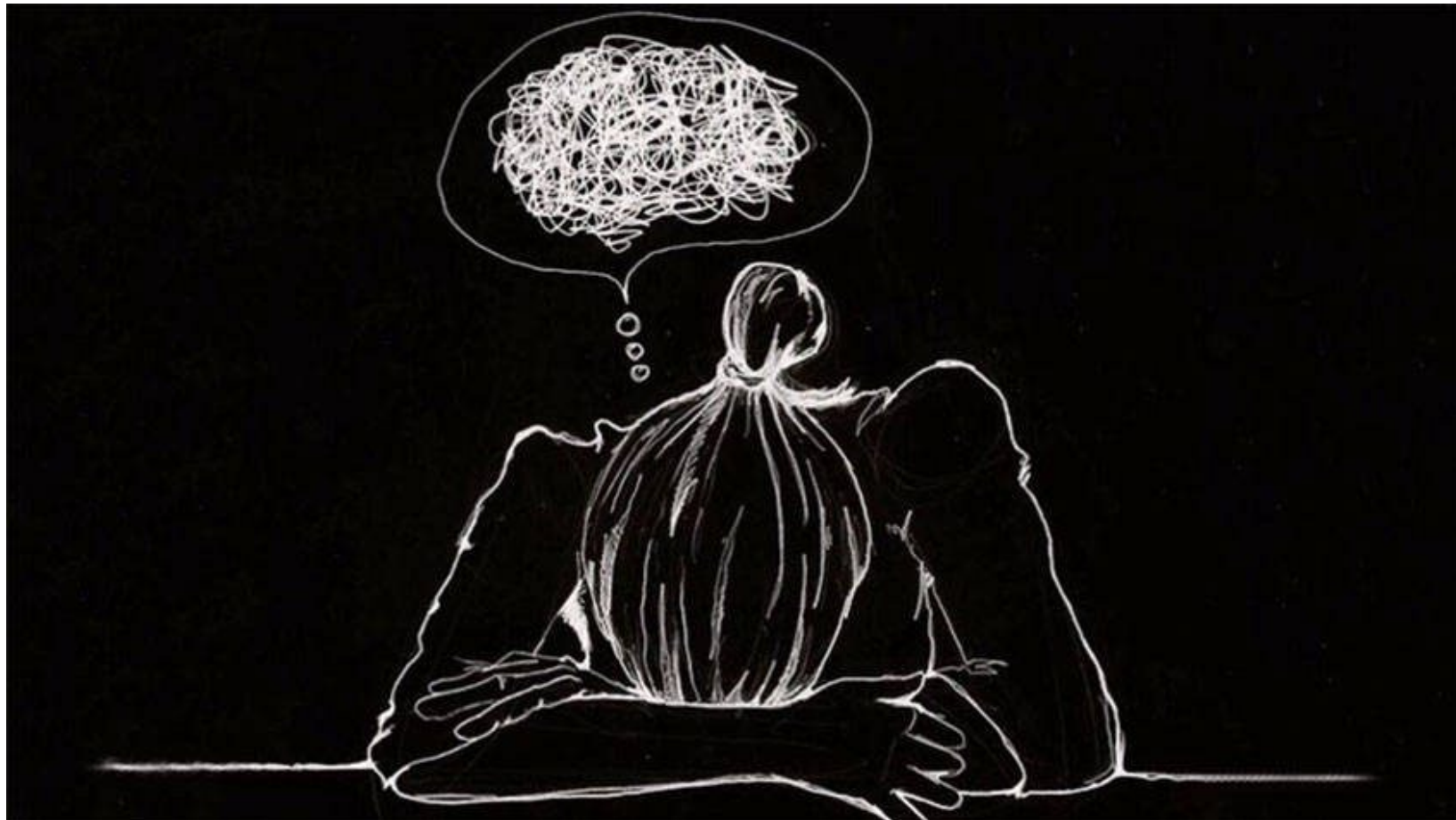
'Settembre 2017:

- Agobiopsia (non diagnostica)
- Termoablazione
- Vertebroplastica

'Gennaio 2018:

- Agobiopsia TC guidata non diagnostica





D.M.D, F, 60 aa – Frattura Patologica T12

'Settembre 2017:

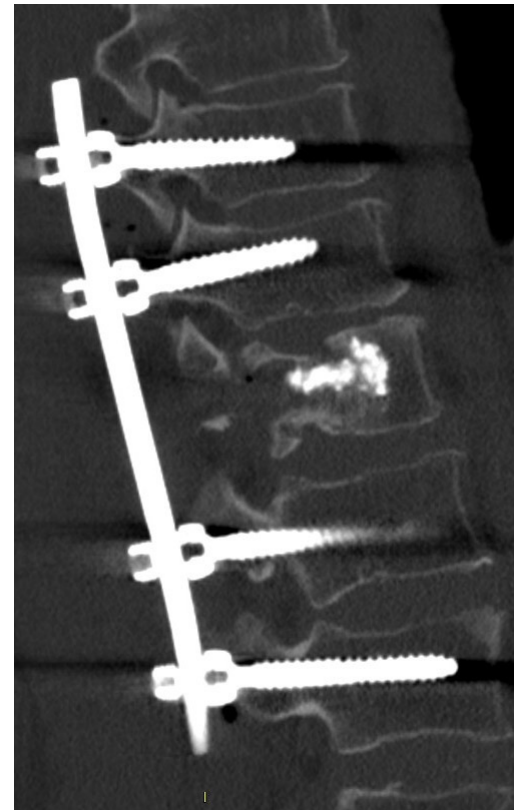
- Agobiopsia (non diagnostica)
- Termoablazione
- Vertebroplastica

'Gennaio 2018:

- Agobiopsia TC guidata non diagnostica

'Marzo 2018:

- Stabilizzazione per via posteriore e biopsia incisionale



D.M.D, F, 60 aa – Frattura Patologica T12

'Settembre 2017:

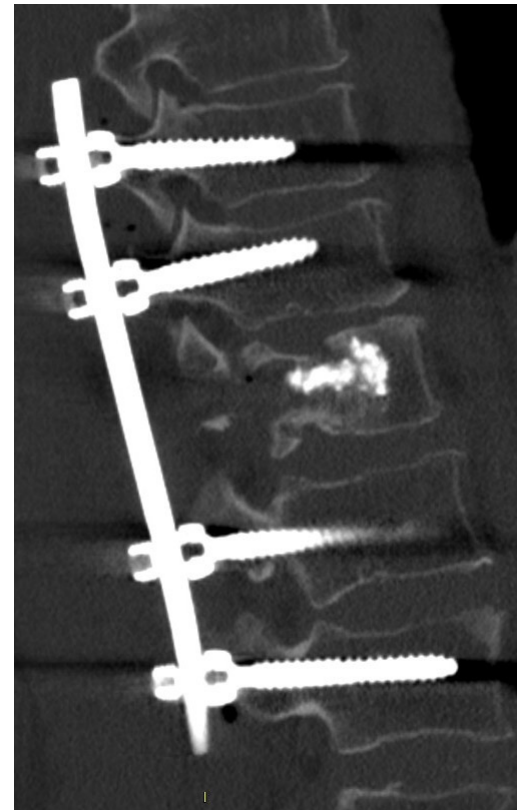
- Agobiopsia (non diagnostica)
- Termoablazione
- Vertebroplastica

'Gennaio 2018:

- Agobiopsia TC guidata non diagnostica

'Marzo 2018:

- Stabilizzazione per via posteriore e biopsia incisionale NON DIAGNOSTICA



Biopsia TC guidata

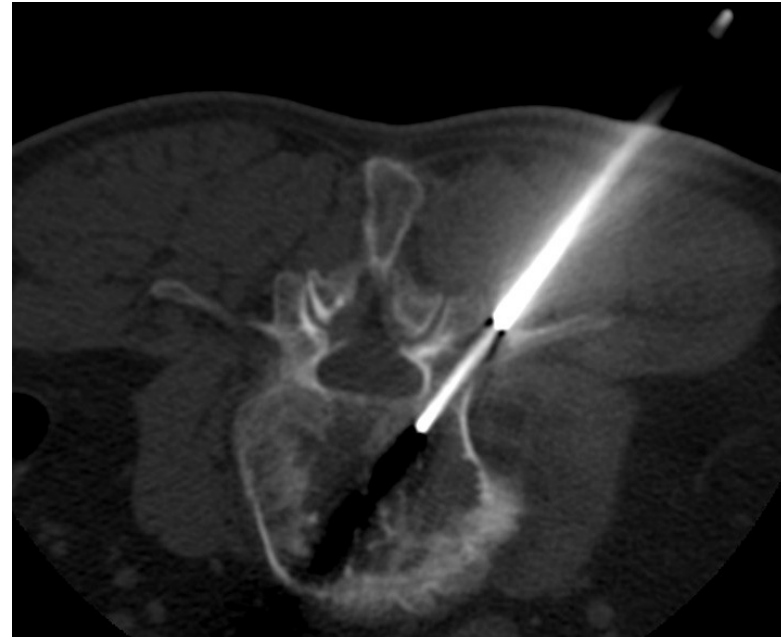
Transpeduncolare

Sicura

Veloce

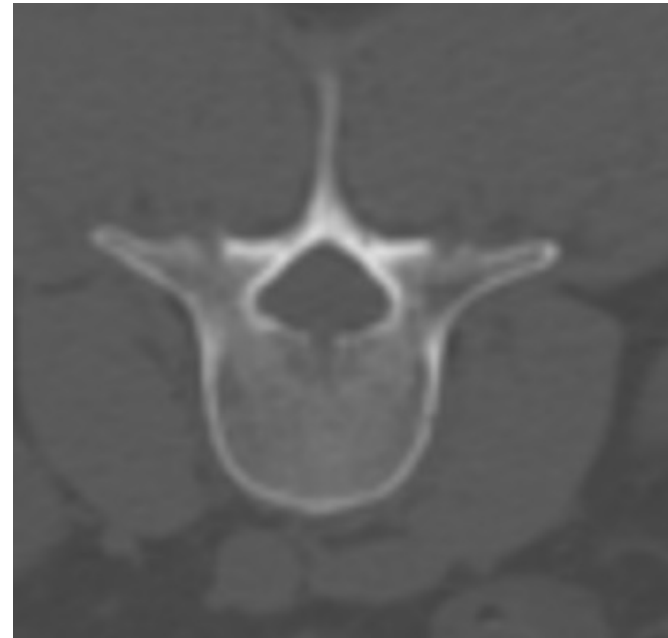
Affidabile

- sensibilità: 94,5%
- specificità: 96,8%

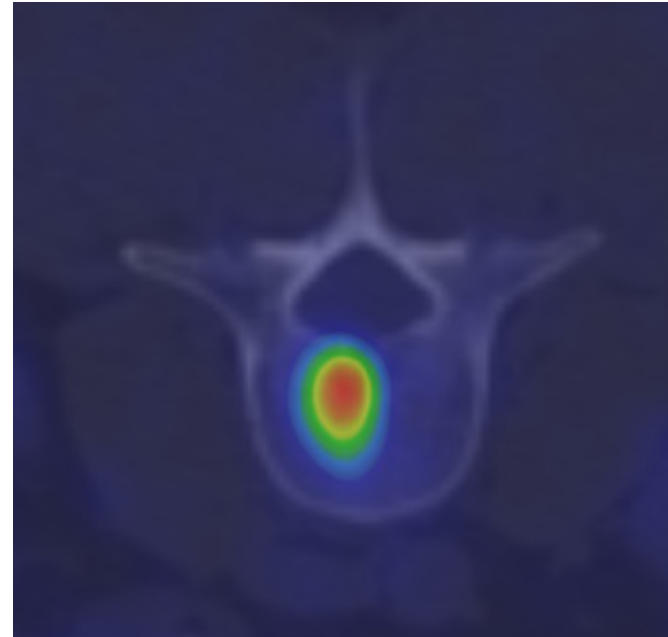


Olscamp A et al. Orthopedics. 1997

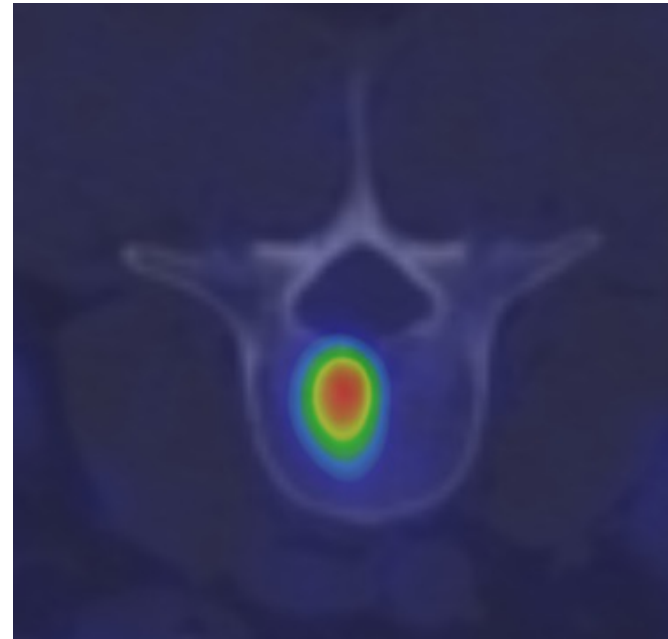
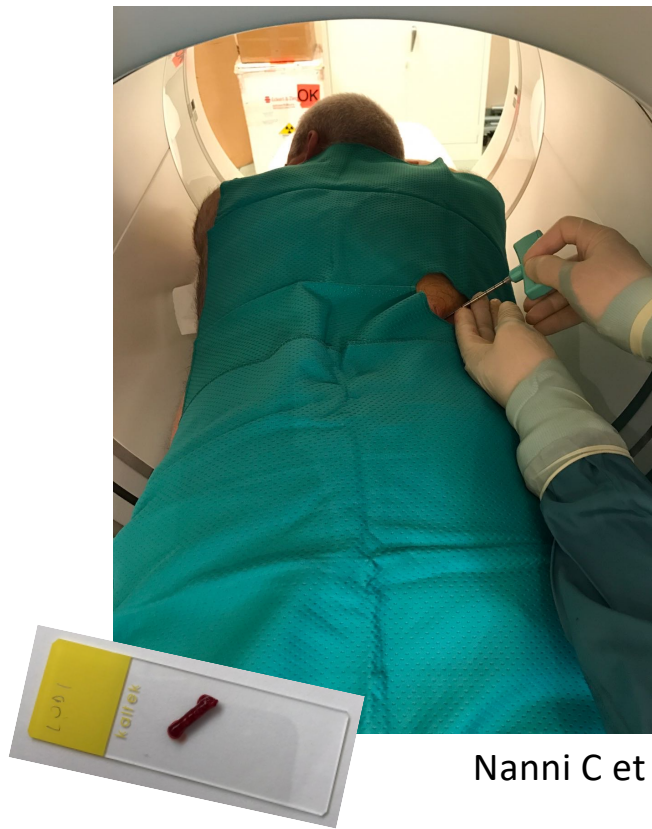Biopsia TC guidata ?



Biopsia PET-TC guidata !!!

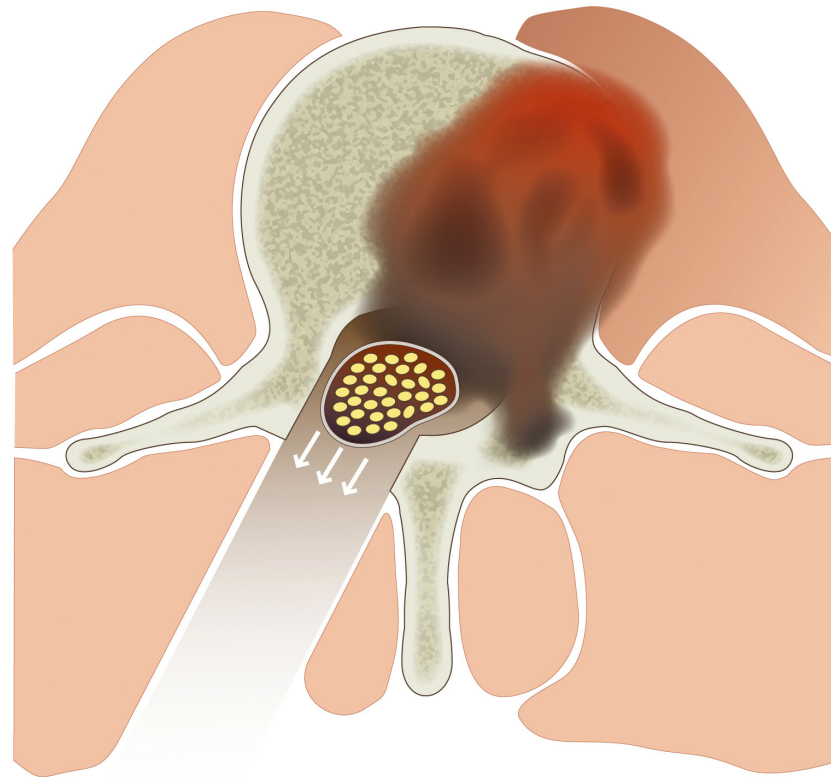


Biopsia PET-TC guidata !!!

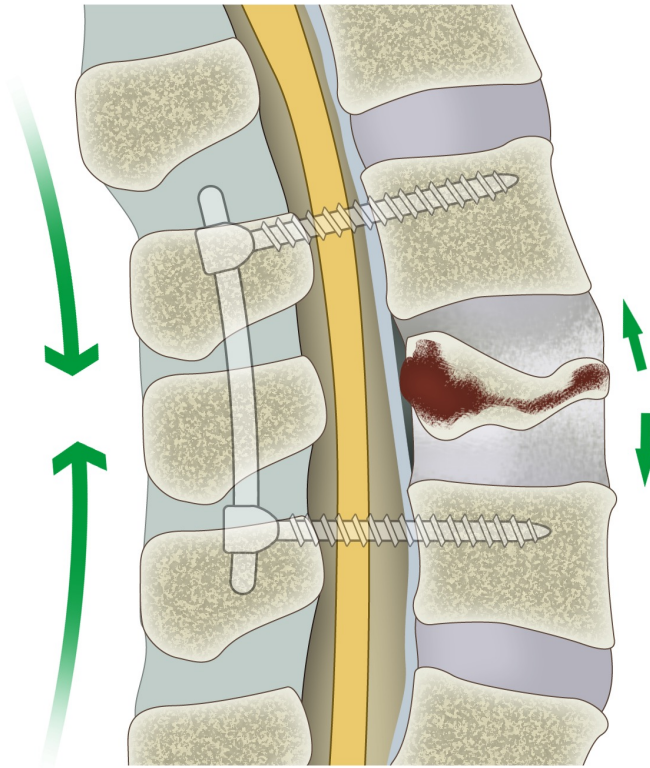


Nanni C et al. Eur J Nucl Med Mol Imaging. 2015

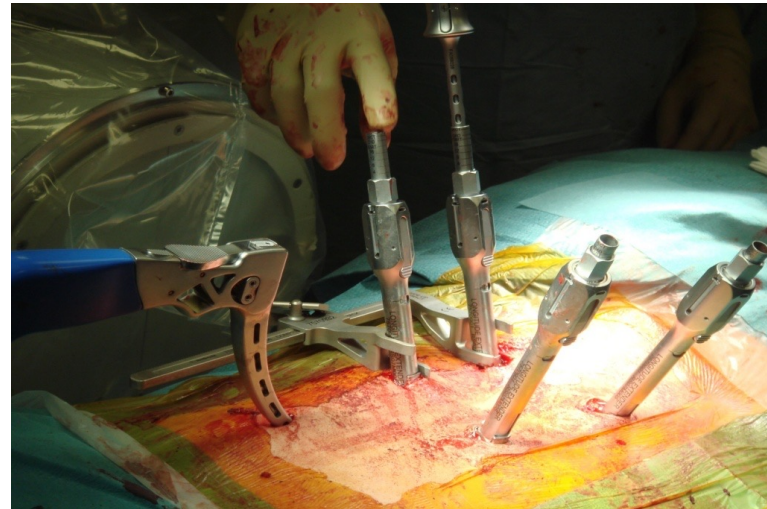Decompressione extralesionale



Decompressione indiretta



Ligamentotassi



Mets of the Spine

- ✓ Improve Quality of Life
 - Surgery always palliative
 - ✧ Stability and motion restoration
- ✧ Neurologic damage prevention or treatment
 - Tumor excision
 - ✧ Local control

Dynamic and evolving management

- Improvements in surgical and non-surgical therapies
- Regeneration therapies for nervous structures

Management guidelines

- De Wald
- Harrington
- Kostuik
- Tokuhashi
- Tomita
- Tokuhashi revisited
- Bauer
- NOMS
- Van Der Linden
- Rades
- Katagiri
- SINS

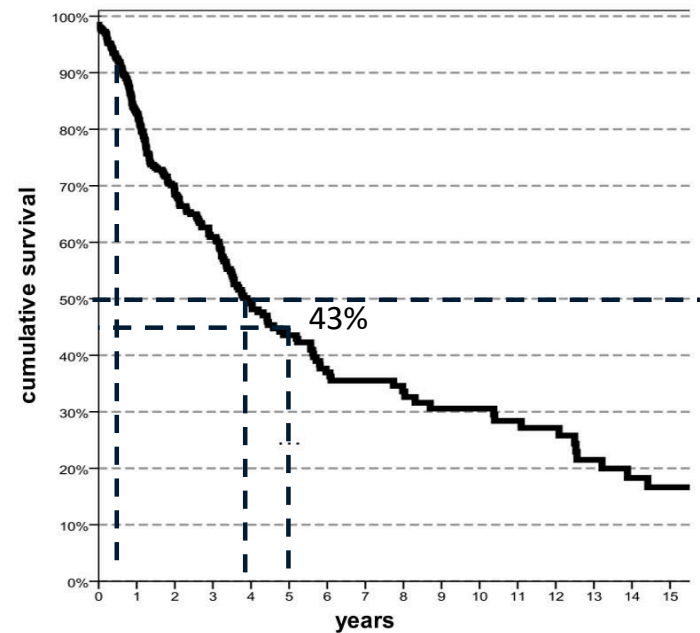


Mets of the Spine

Indications for Surgery:

- ✓Neurological Symptoms
- ✓Instability (impending or actual PF)
- ✓Untractable Pain
- ✓Non RT-sensitive Lesions
- ✓Failure of previous treatments

Mets of the Spine Survival after surgery

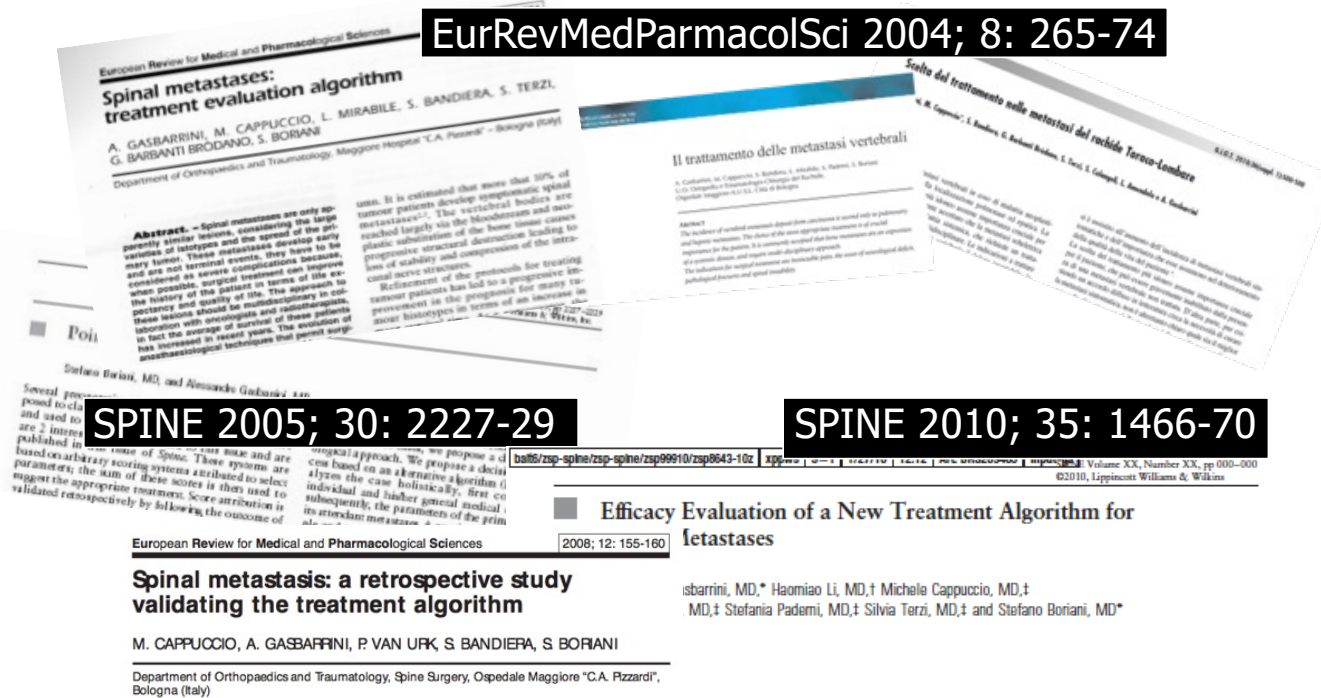


Global survival

5 years	43%
10 years	30%
15 years	17%

Mets of the Spine

Flow-chart for decision making process

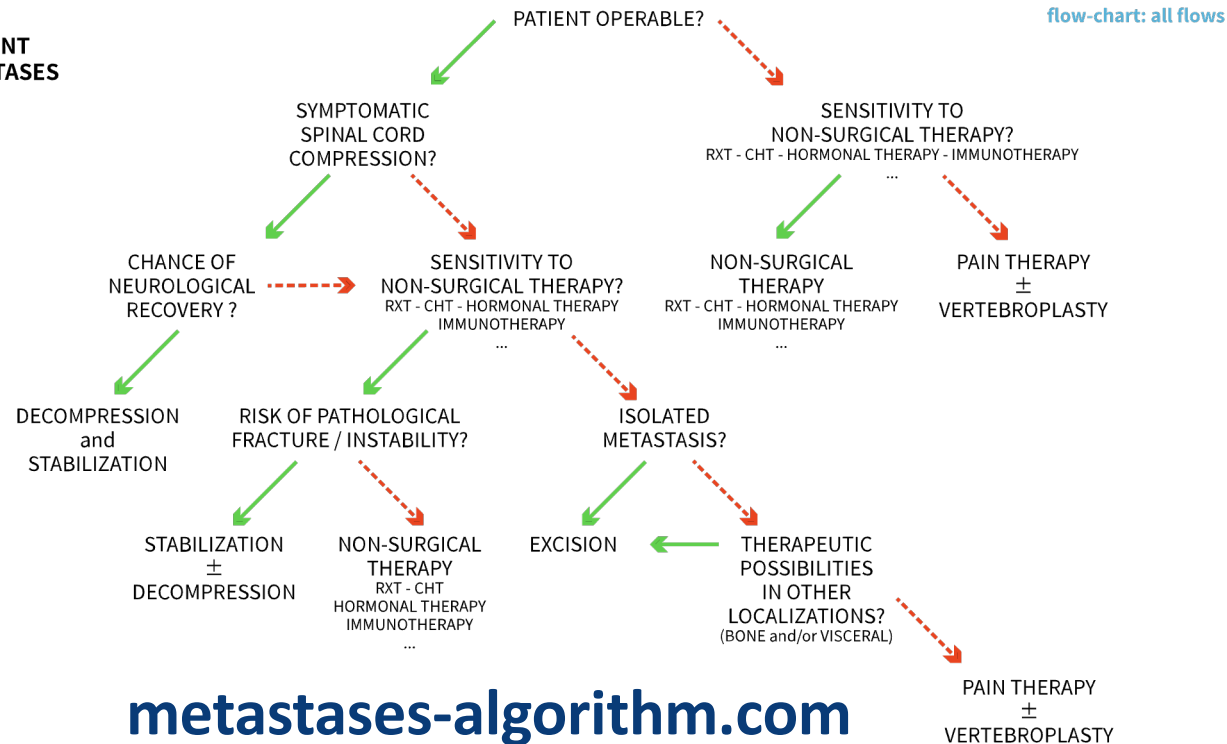




SPINAL
METASTASES
ALGORITHM

Spinal Metastases *Decision making flow-chart*

**FLOW-CHART
FOR THE TREATMENT
OF SPINAL METASTASES**



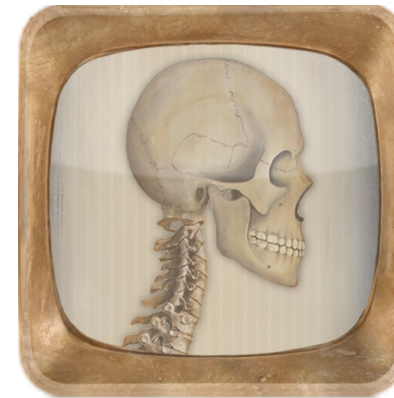

**Algorithm for decision-making
process of spine
metastatic diseases**



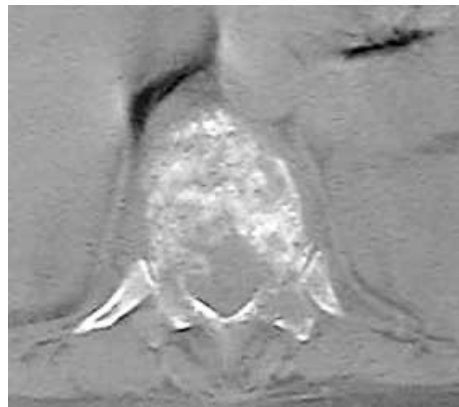
 SPINE SURGERY RIZZOLI INSTITUTE - BOLOGNA - ITALY

Free WebApp



iSMT
metastases-algorithm.com

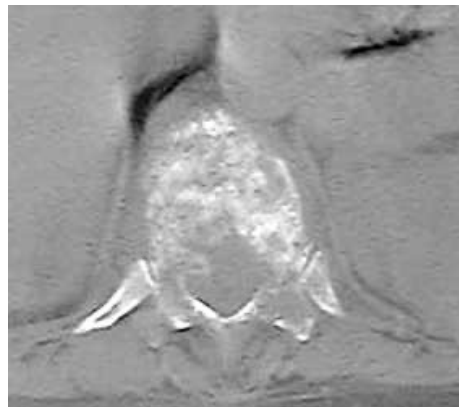
C.T., 43 aa., ASA: 3
Meta solitaria di T12
da Carcinoma Mammario
Karnofsky: 90%
Frankel: E
No frattura patologica
Δt: 3 anni



“En Bloc”

Tokuhashi score		SCORE
1. General function status-Karnofsky score (Ks)		
Bad	(Ks 10-40%)	0
Medium	(Ks 50-70%)	1
Good	(Ks 80-100%)	2
2. N° of extraspinal bone metastasis foci (Tc ^{99m} MDP Scan)		
> 0 = 3		0
1-2		1
0		2
3. N° of spinal metastasis foci (MRI)		
> 0 = 3		0
2		1
1		2
4. Metastases at internal organs (CT chest, US abdomen)		
No surgical treatment option		0
Surgical treatment option		1
No metastases		2
5. Primary cancer diagnosis		
Lung, stomach		0
Kidney, liver, uterus, unknown		1
Thyroid, prostate, breast, rectum		2
6. Spinal cord injury (Frankel score)		
Complete	(Frankel A or B)	0
Incomplete	(Frankel C or D)	1
None	(Frankel E)	2
Total		12

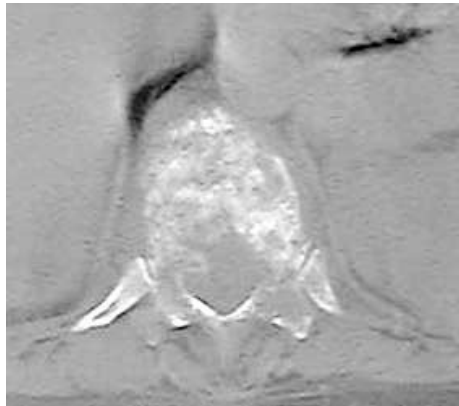
C.T., 43 aa., ASA: 3
 Meta solitaria di T12
 da Carcinoma Mammario
 Karnofsky: 90%
 Frankel: E
 No frattura patologica
 Δt: 3 anni



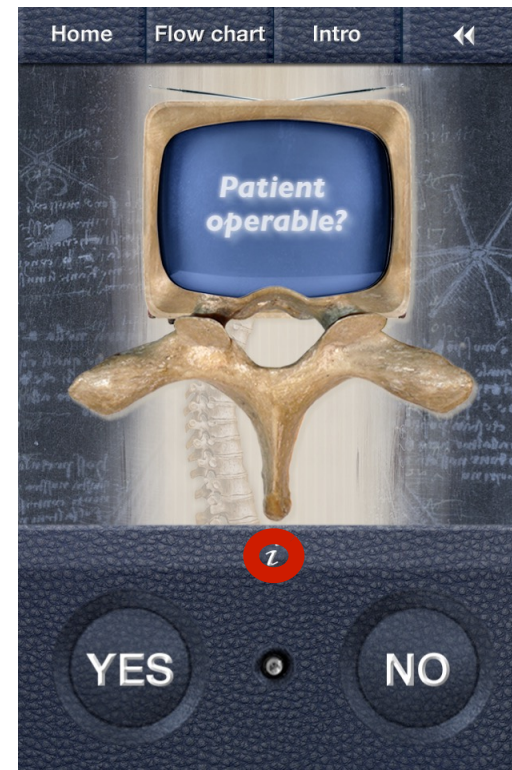
“En Bloc”

Tomita score	score
Grade of malignancy	
- Slow growth	1
- Moderate growth	2
- Rapid growth	4
Visceral metastases	
- No metastasis	0
- Treatable	2
- Untreatable	4
Bone metastases	
- Solitary/isolated	1
- Multiple	2
<i>total</i>	3

C.T., 43 y.o., ASA: 3
Solitary methastasis of T12
from Breast carcinoma
Karnofsky: 90%
Frankel: E
No pathological fracture
 Δt : 3 years



C.T., 43 y.o., ASA: 3
Solitary methastasis of T12
from Breast carcinoma
Karnofsky: 90%
Frankel: E
No pathological fracture
 Δt : 3 years



Open in Safari ← **Back**

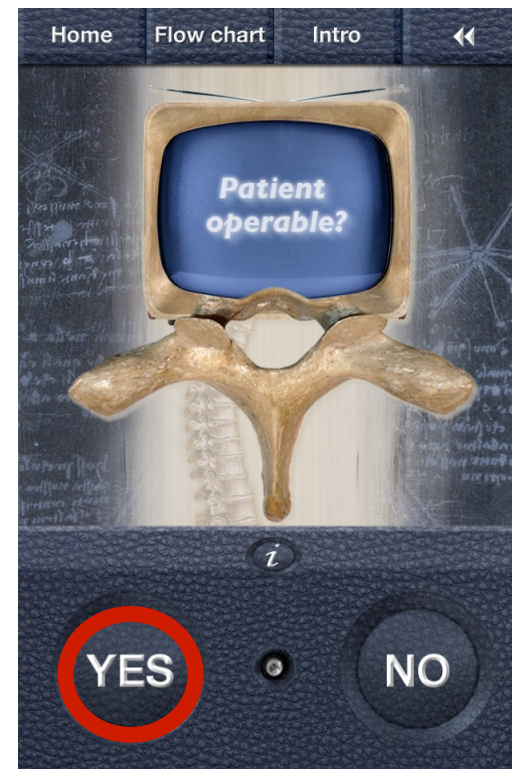
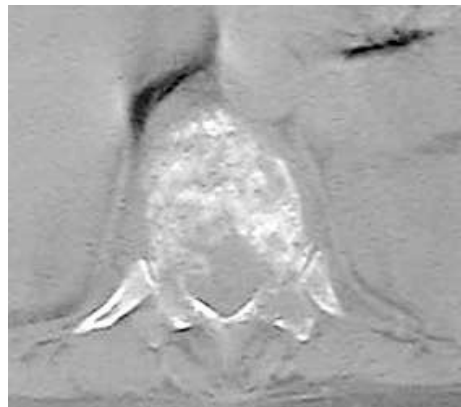
Patient operable

Determination of operability involves a system evaluation of the general condition of the patient, involving the presence and severity of comorbidities, the oncological prognosis and the willingness of the patient to undergo mayor surgery. At this point the opinion from the Anesthesiologist and Oncologist are invaluable. As a general rule, patients with ASA scores 4 or 5, or with an expected survival of less than 3 months are no surgical candidates. ASA 3 patients fall in an intermediate situation and should be reviewed case by case. Some useful evaluation tools:

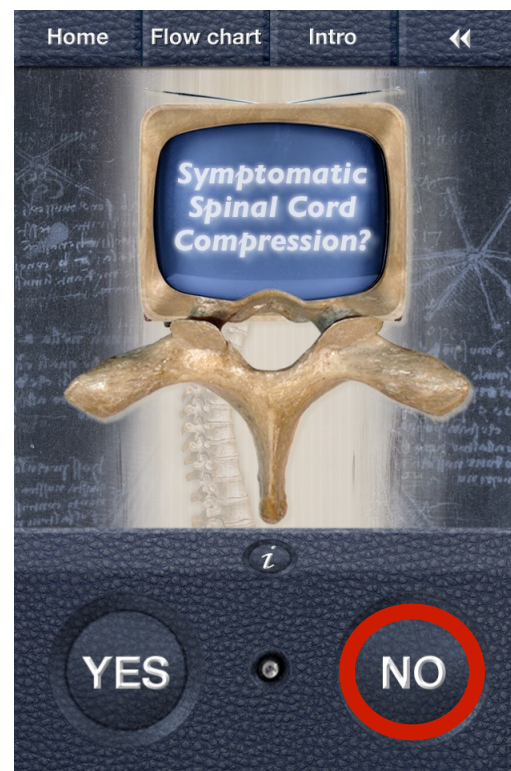
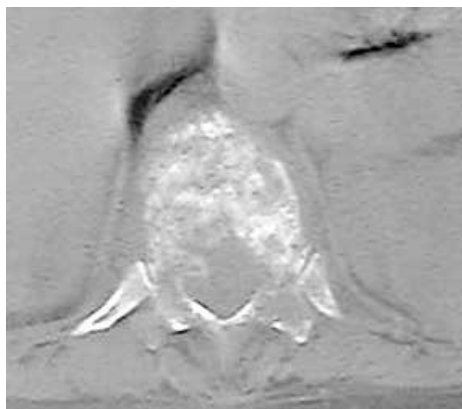
- ASA classification**
- Karnofsky score**
- ECOG score**

ASA physical status classification.
It is a system for assessing the fitness of patients before surgery. Was adopted in 1963 by the American Society of Anesthesiologists (ASA).

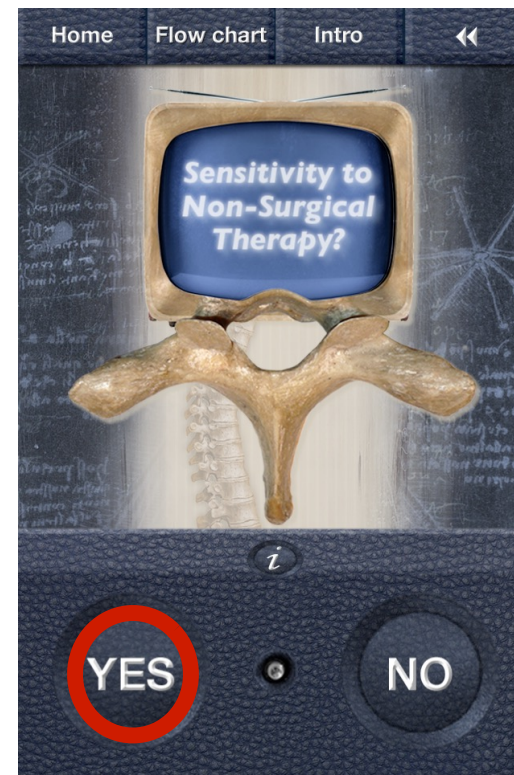
C.T., 43 y.o., ASA: 3
Solitary methastasis of T12
from Breast carcinoma
Karnofsky: 90%
Frankel: E
No pathological fracture
 Δt : 3 years



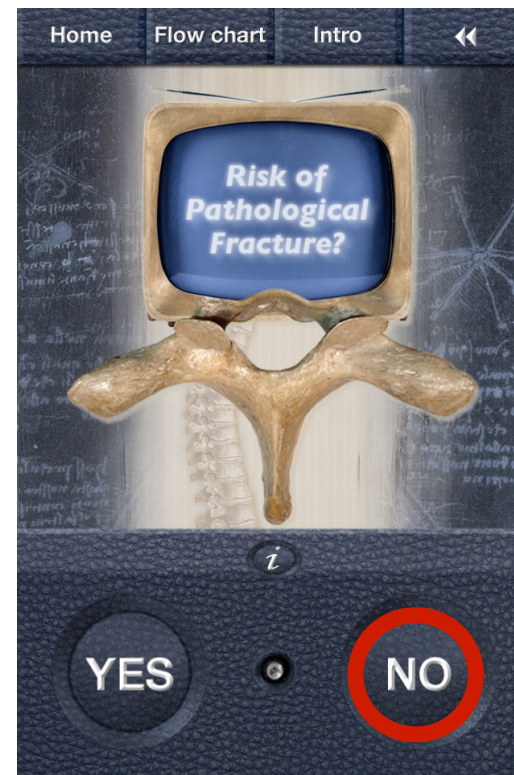
C.T., 43 y.o., ASA: 3
Solitary methastasis of T12
from Breast carcinoma
Karnofsky: 90%
Frankel: E
No pathological fracture
 Δt : 3 years



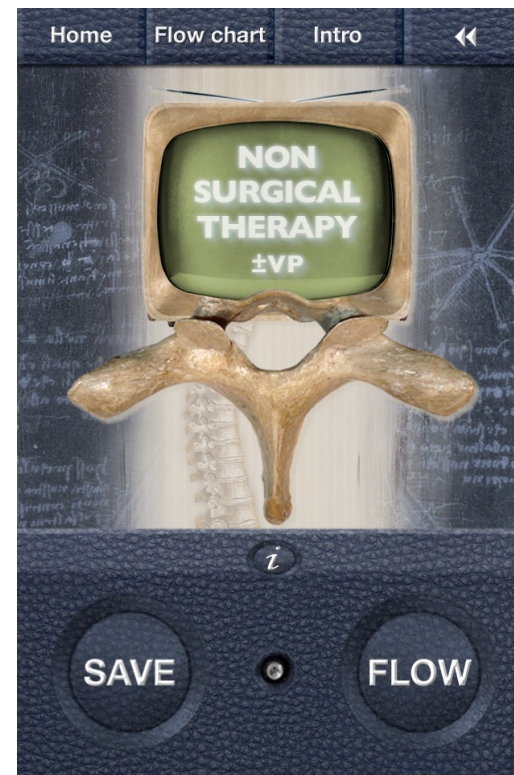
C.T., 43 y.o., ASA: 3
Solitary methastasis of T12
from Breast carcinoma
Karnofsky: 90%
Frankel: E
No pathological fracture
 Δt : 3 years



C.T., 43 y.o., ASA: 3
Solitary methastasis of T12
from Breast carcinoma
Karnofsky: 90%
Frankel: E
No pathological fracture
 Δt : 3 years



C.T., 43 y.o., ASA: 3
Solitary methastasis of T12
from Breast carcinoma
Karnofsky: 90%
Frankel: E
No pathological fracture
 Δt : 3 years

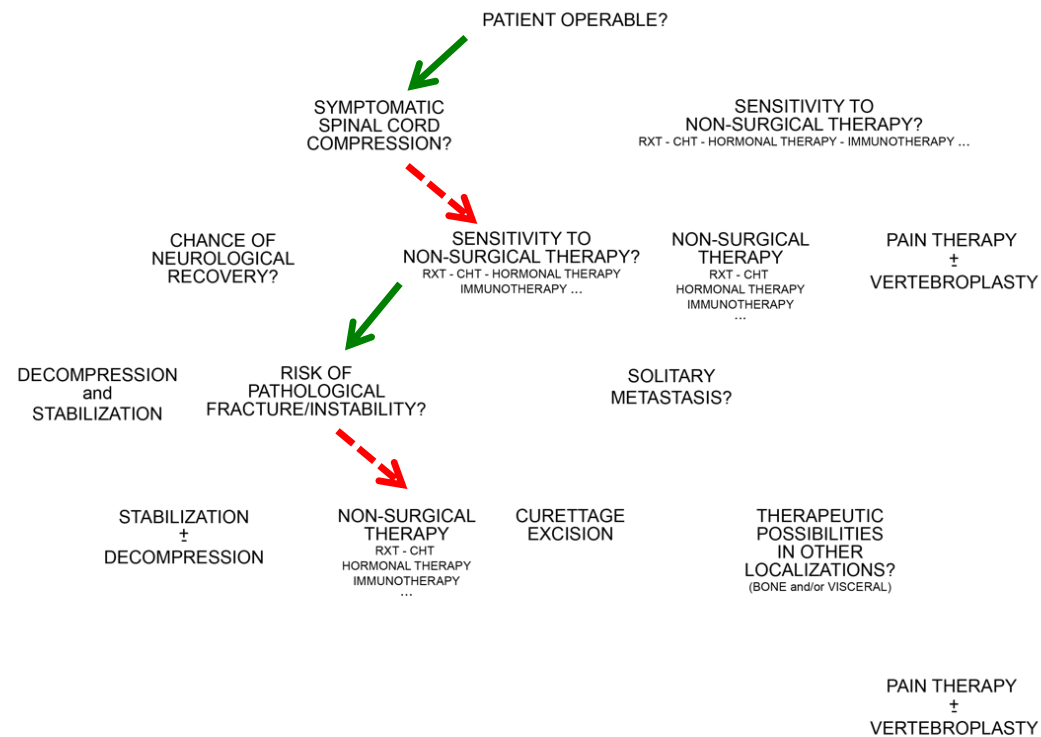




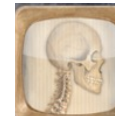SPINAL
METASTASES
ALGORITHM

Spinal Metastases

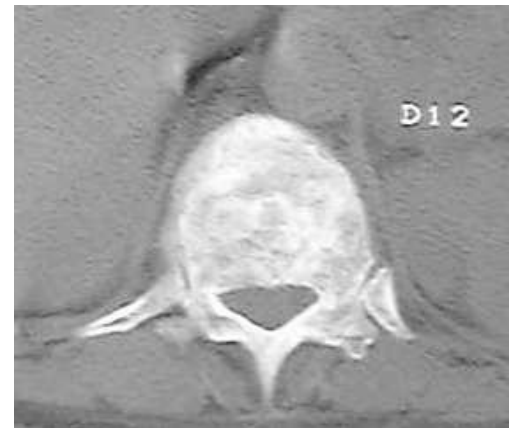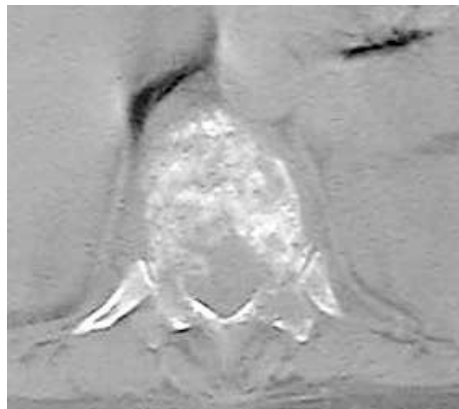Decision making flow-chart



C.T., 43 y.o., ASA: 3
Solitary methastasis of T12
from Breast carcinoma
Karnofsky: 90%
Frankel: E
No pathological fracture
 Δt : 3 years



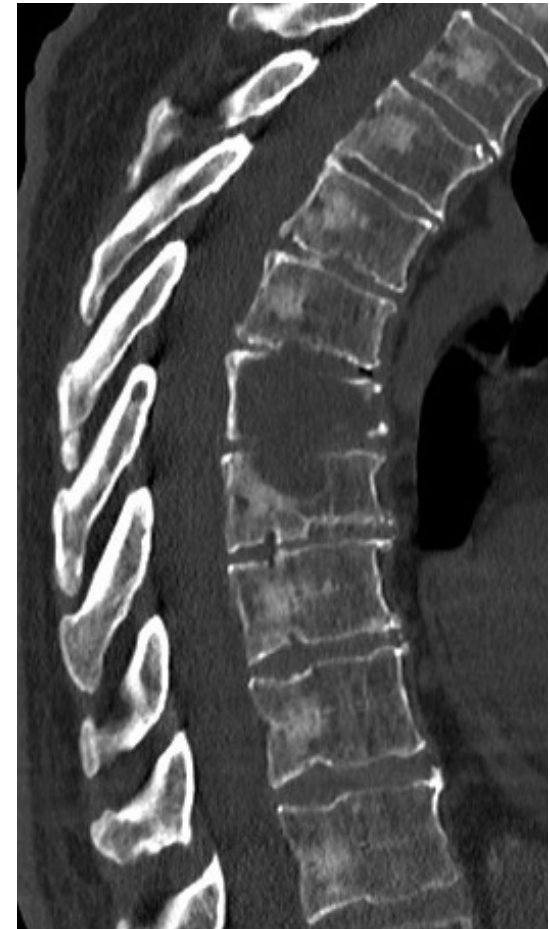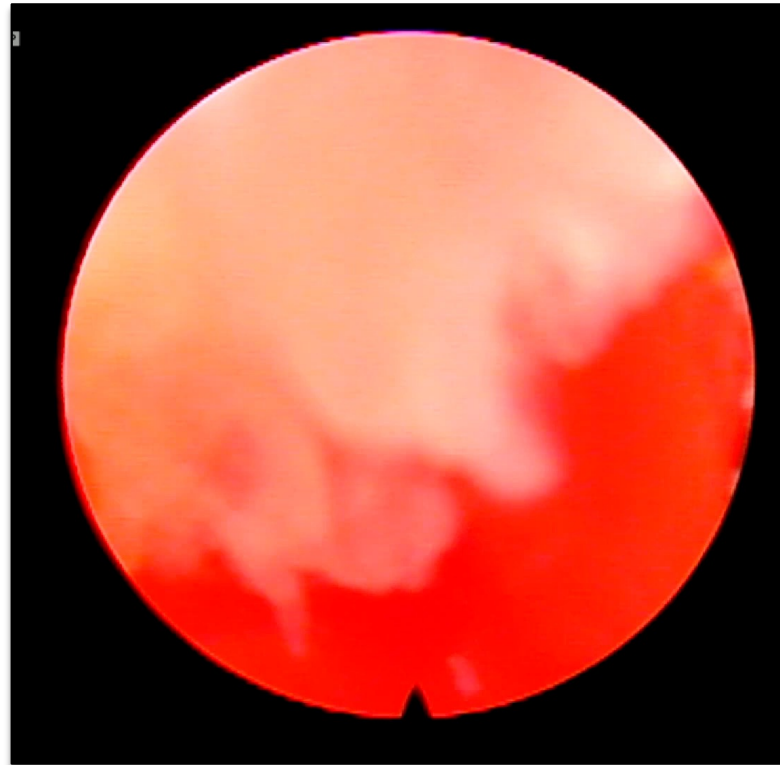
iSMT



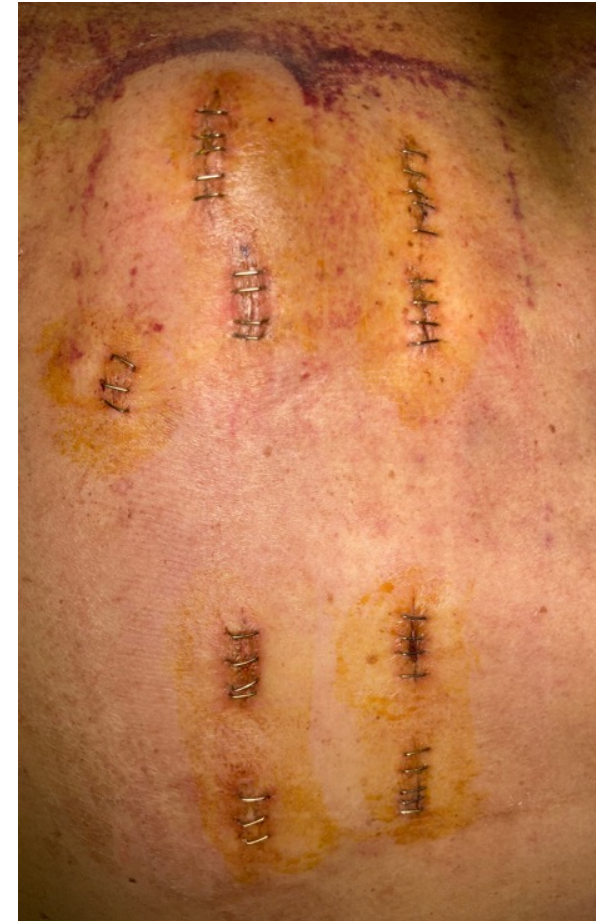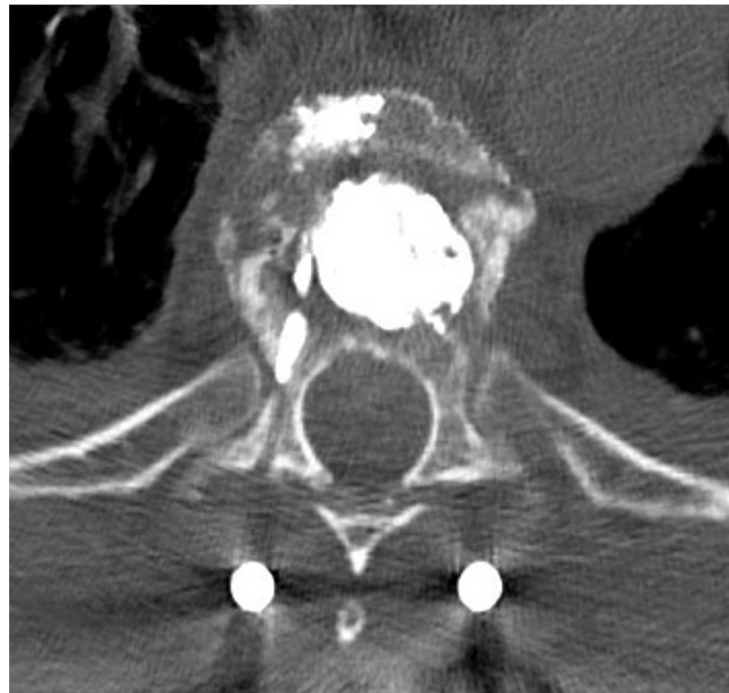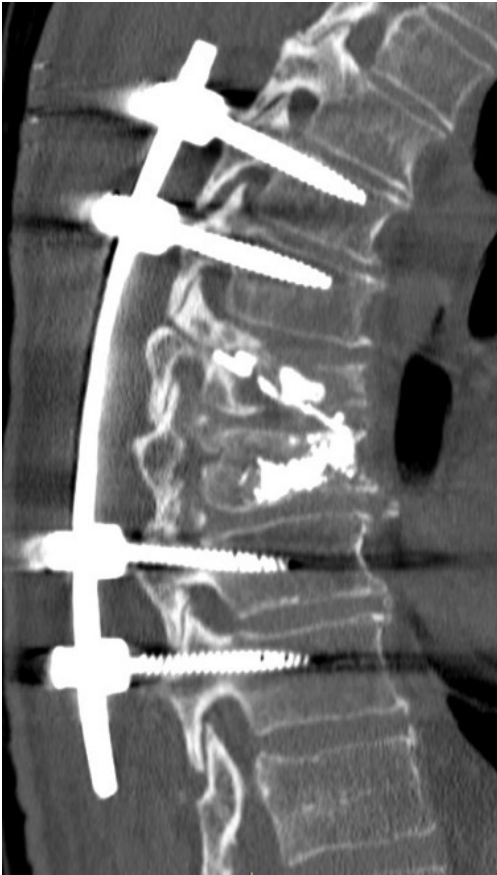
9 months after ormono-therapy

Endoscopic Debulking?

M.R, 74 yrs,
Fracture of T7 in
Myeloma

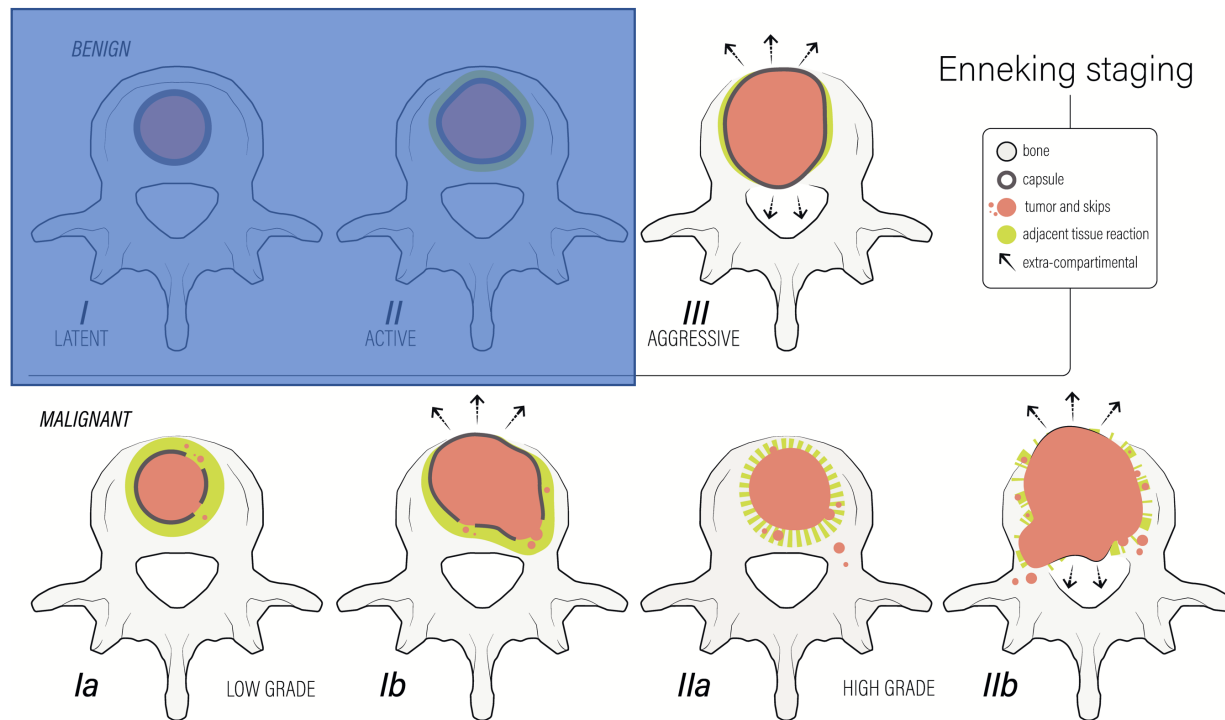


Endoscopic Debulking



Tumori Primitivi Vertebrali

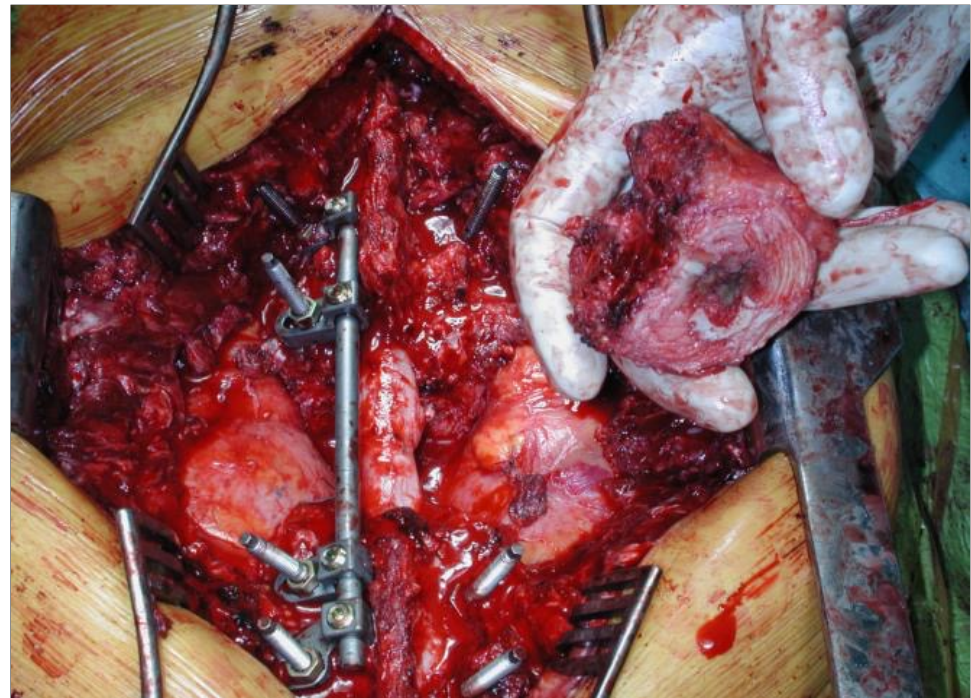
Enneking Staging System (1980)




Stage III = Stages I and II + regional and or distant metastases

Resezione in blocco nella colonna

- L'intero tumore rivestito da un guscio di tessuto non patologico
- Lo spessore del guscio è chiamato “**MARGINE**”



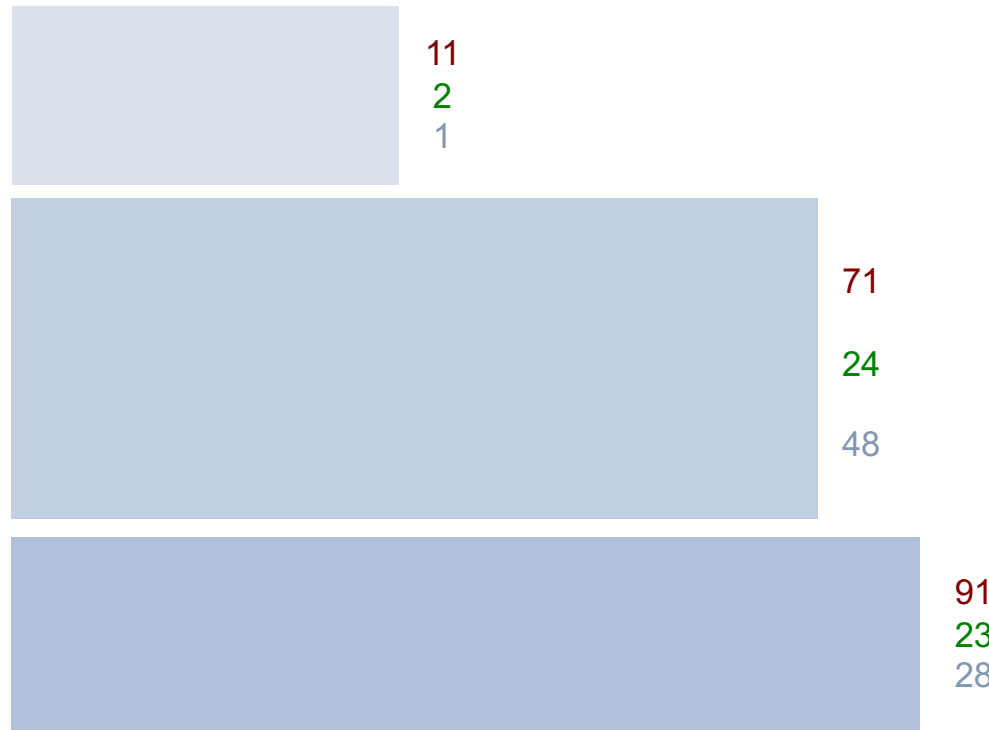
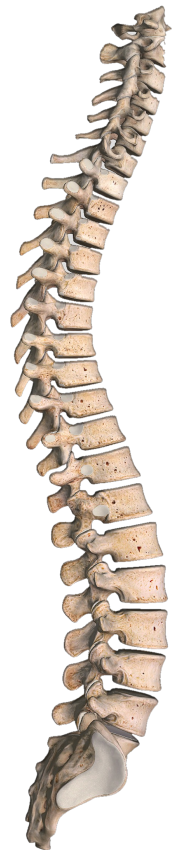Tumore



Resezione en bloc



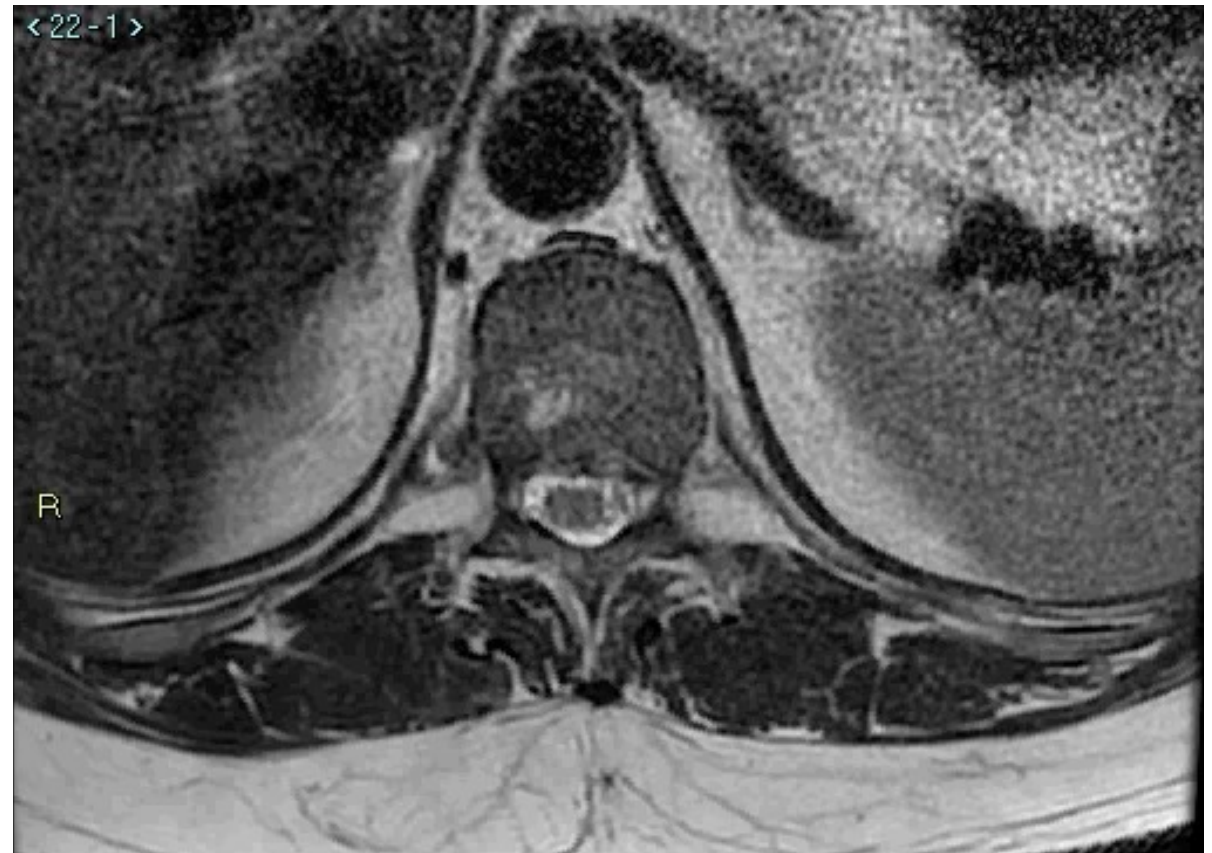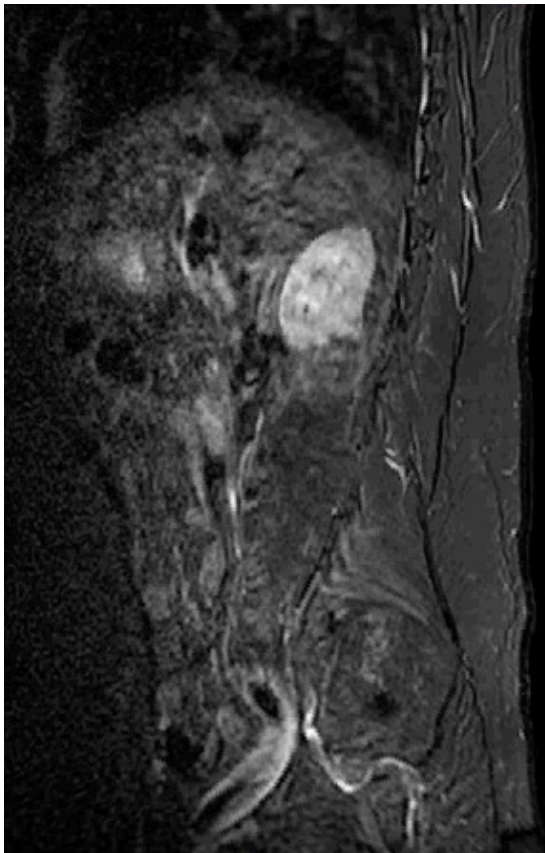
Curettage



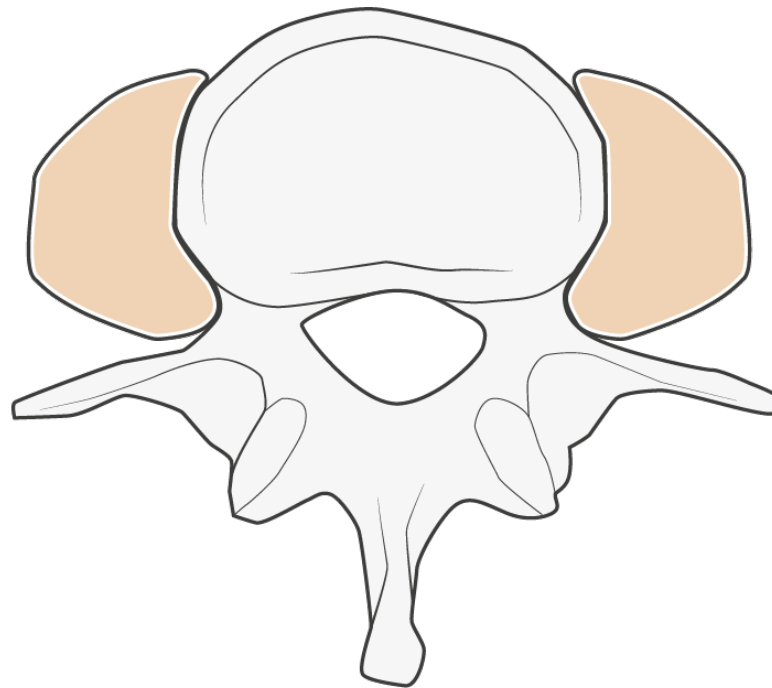
En bloc series
1996-2022
304

Malignant
Benign Aggressive
Metastases

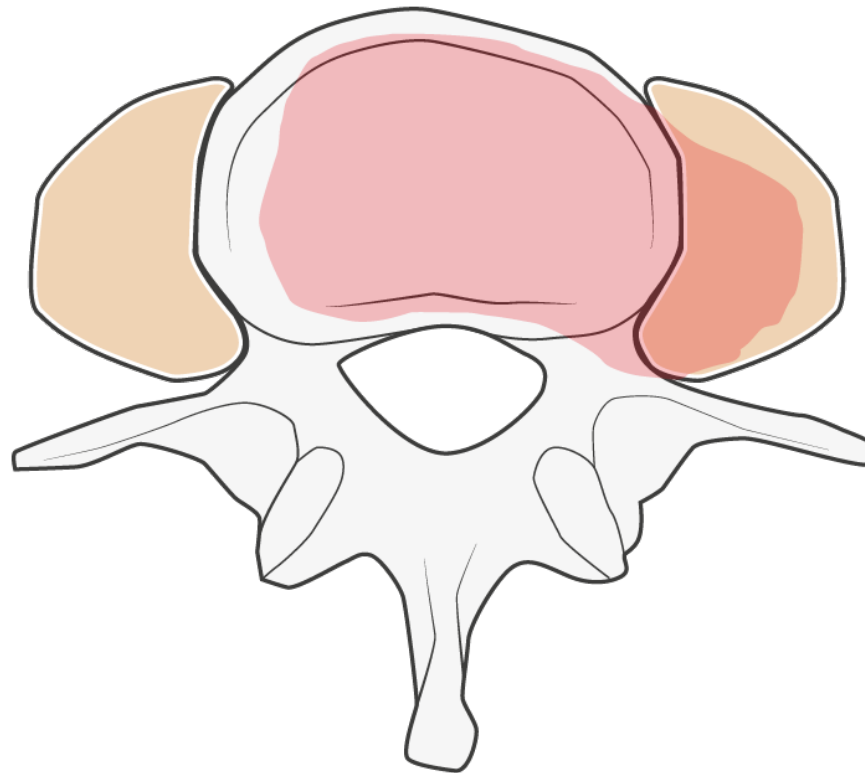
M.A. 52 yo, male – L3 Chordoma



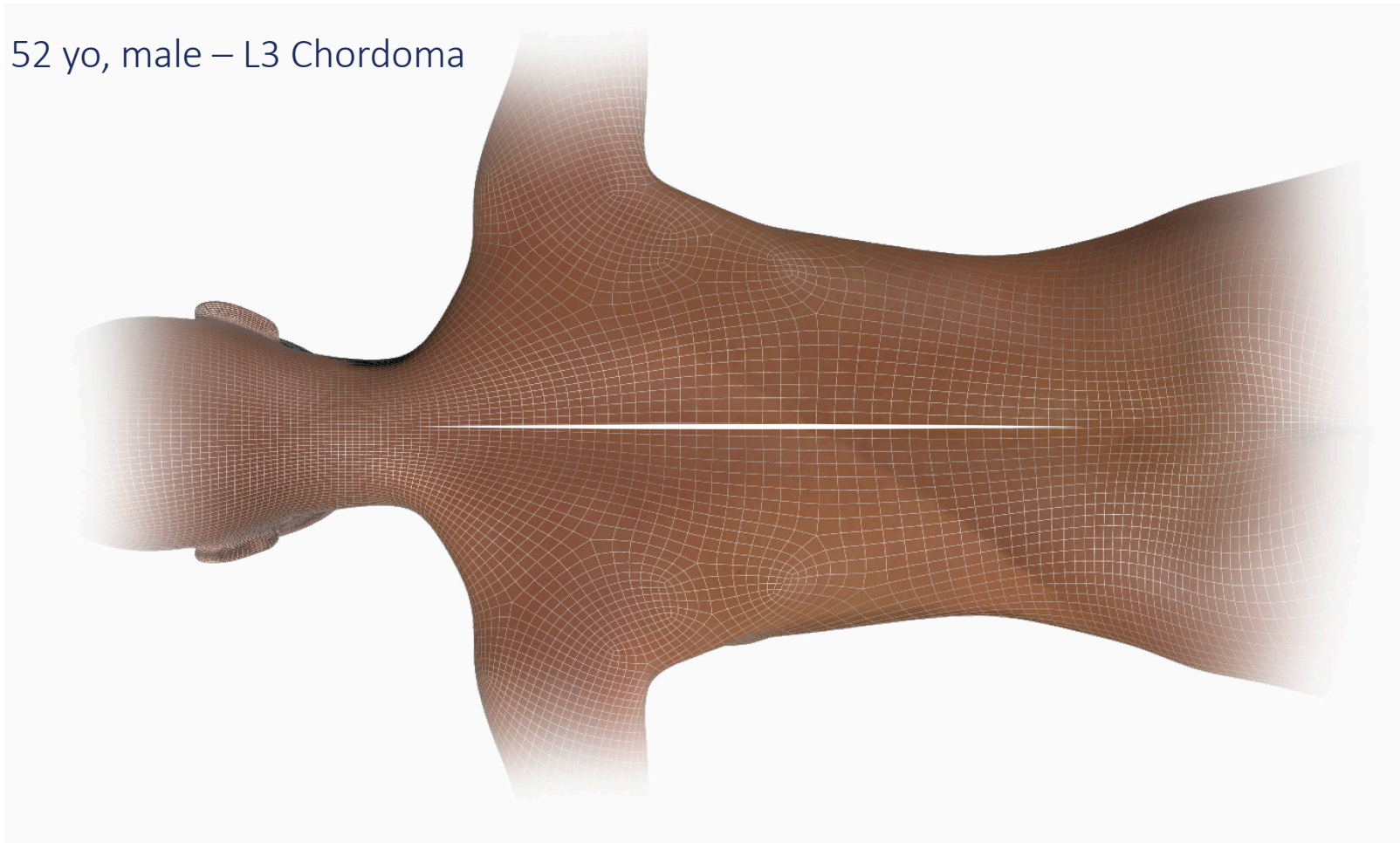
M.A. 52 yo, male – L3



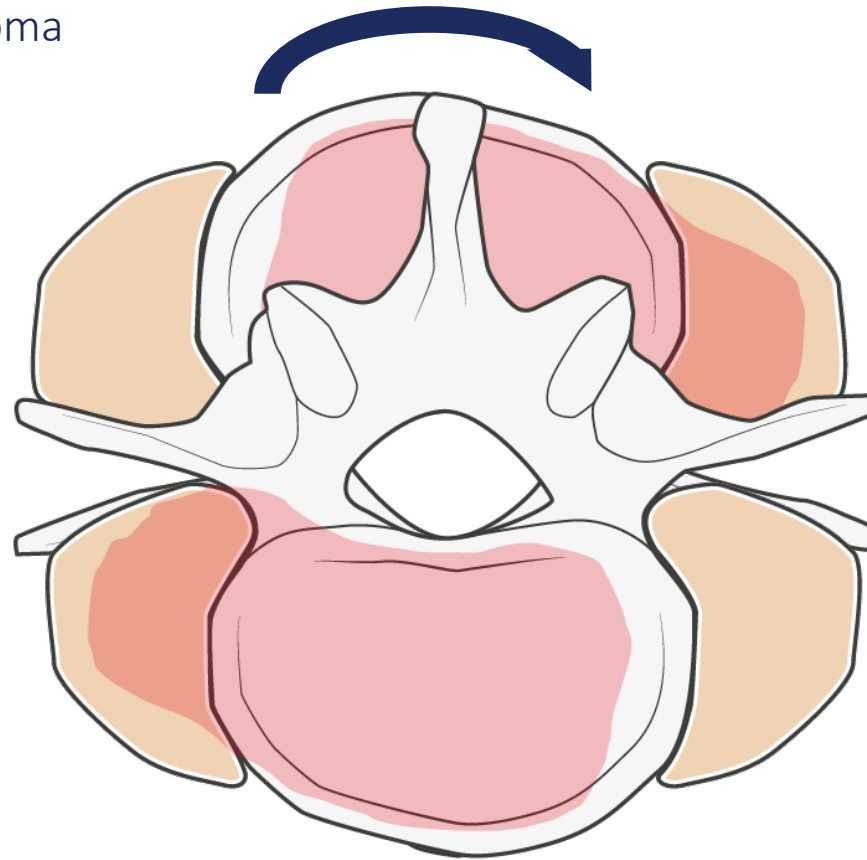
M.A. 52 yo, male – L3 Chordoma



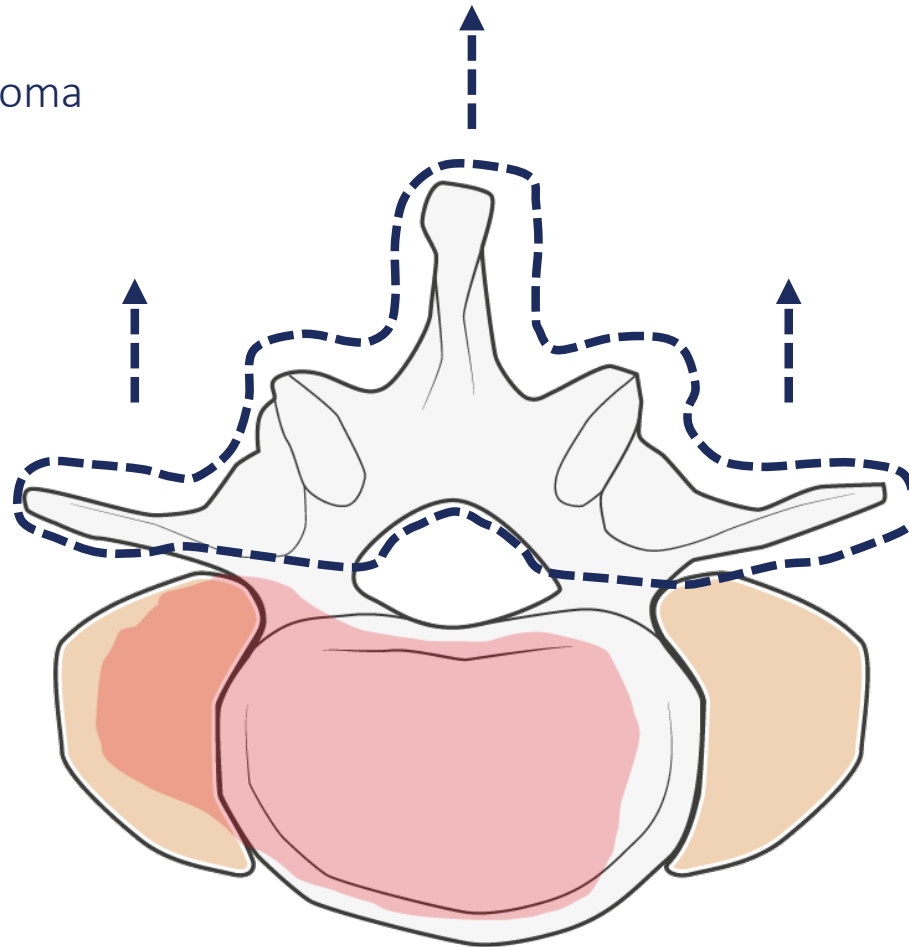
M.A. 52 yo, male – L3 Chordoma



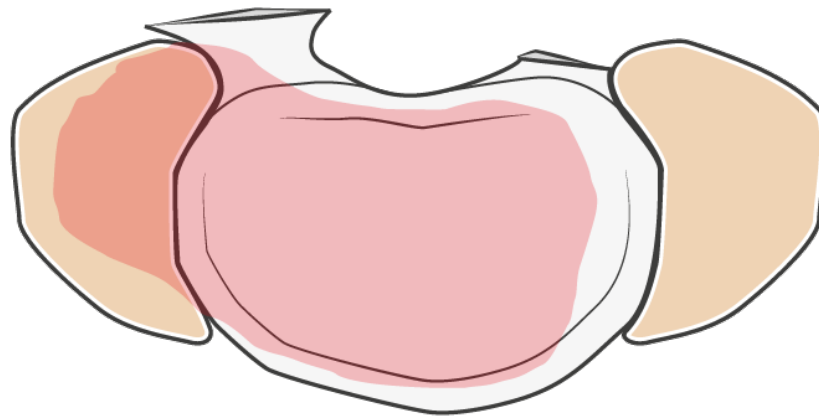
M.A. 52 yo, male – L3 Chordoma



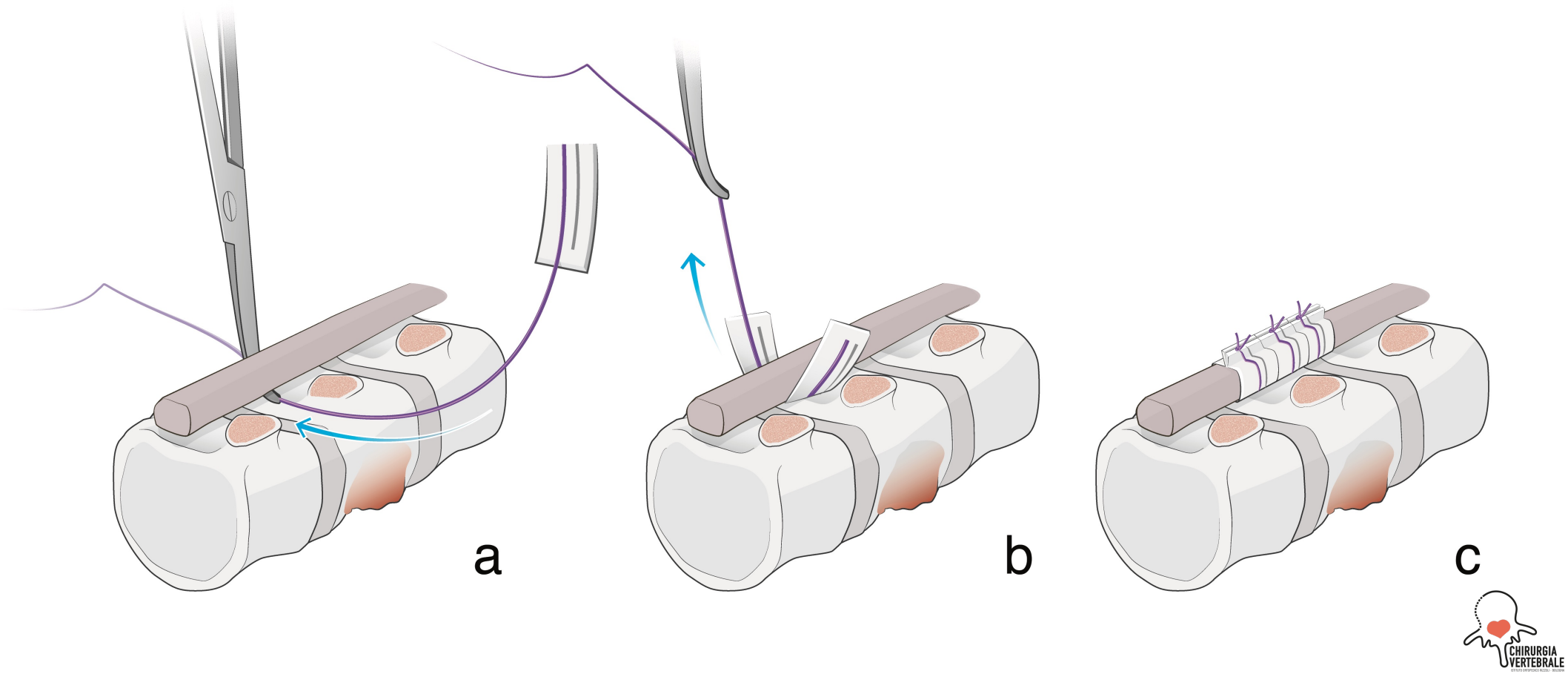
M.A. 52 yo, male – L3 Chordoma

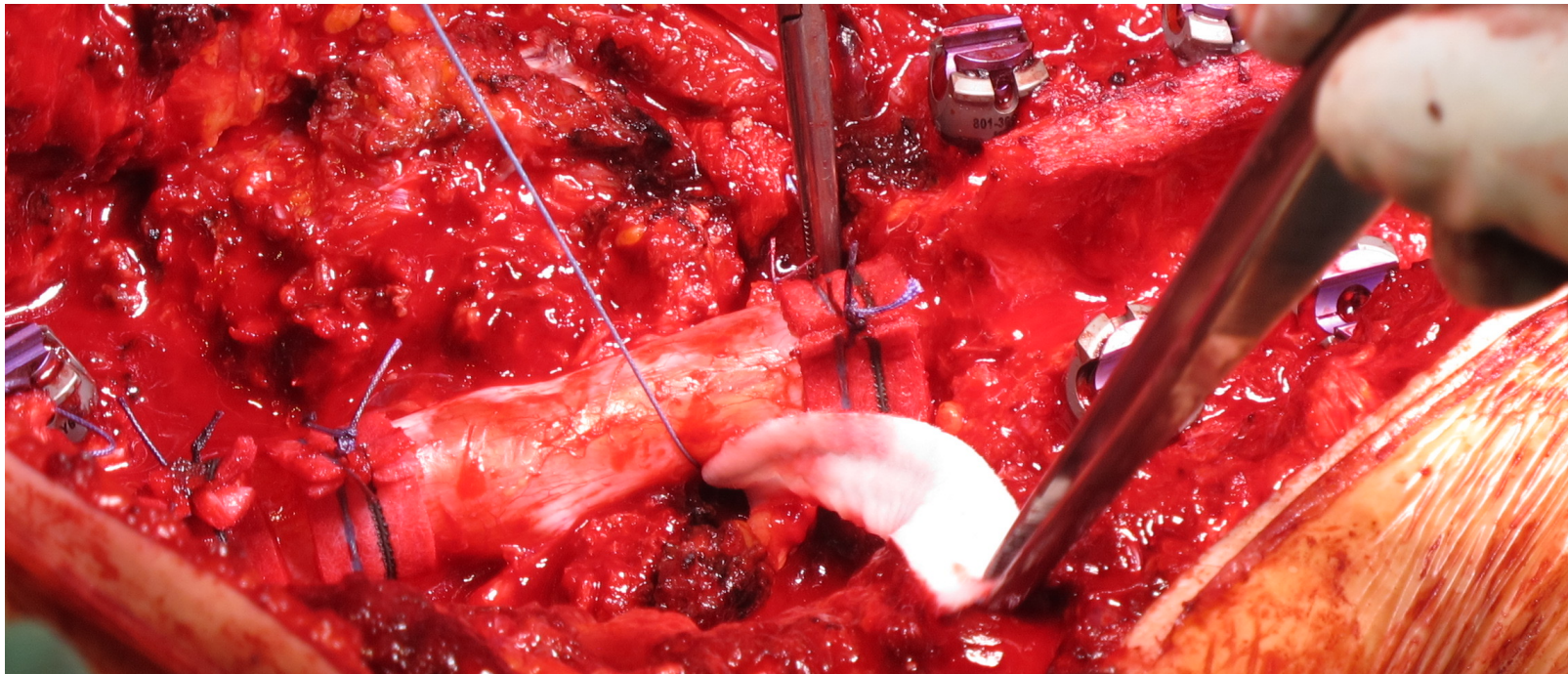


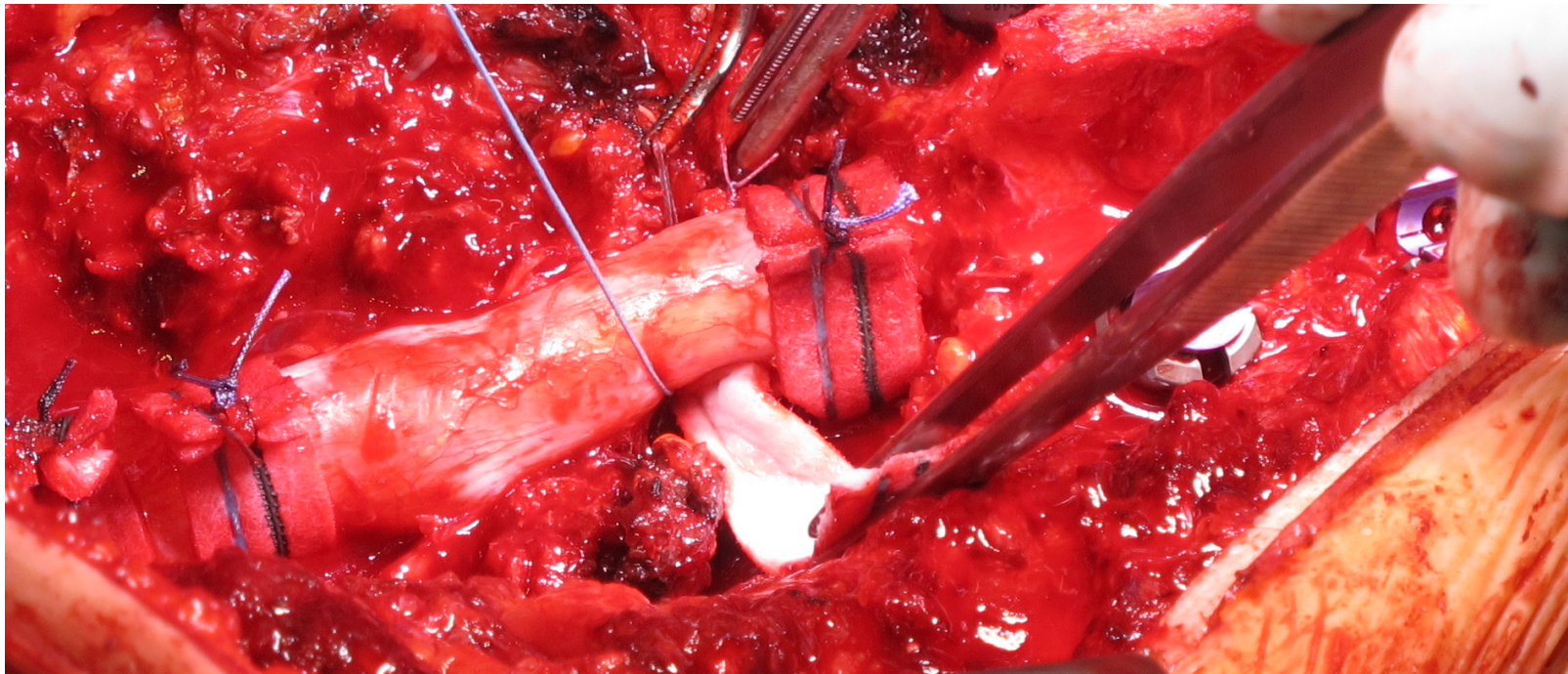
M.A. 52 yo, male – L3 Chordoma



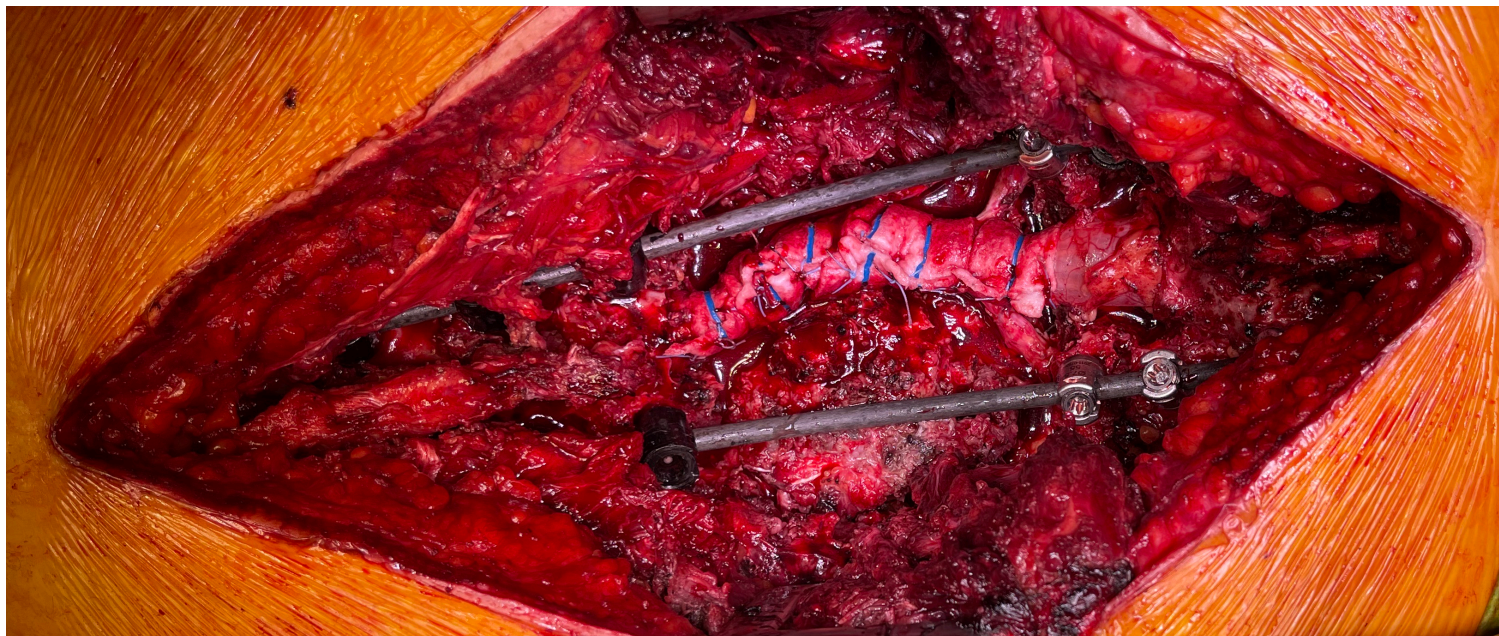
M.A. 52 yo, male – L3 Chordoma







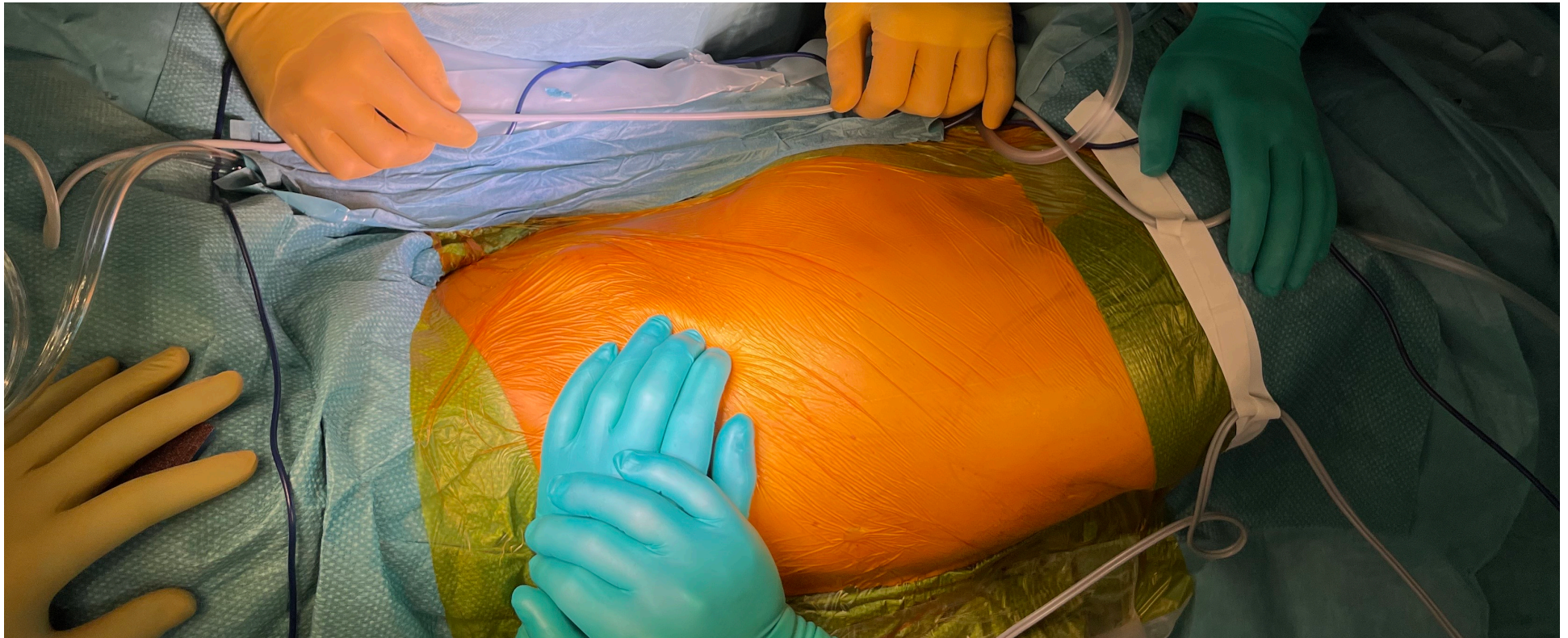
M.A. 52 yo, male – L3 Chordoma



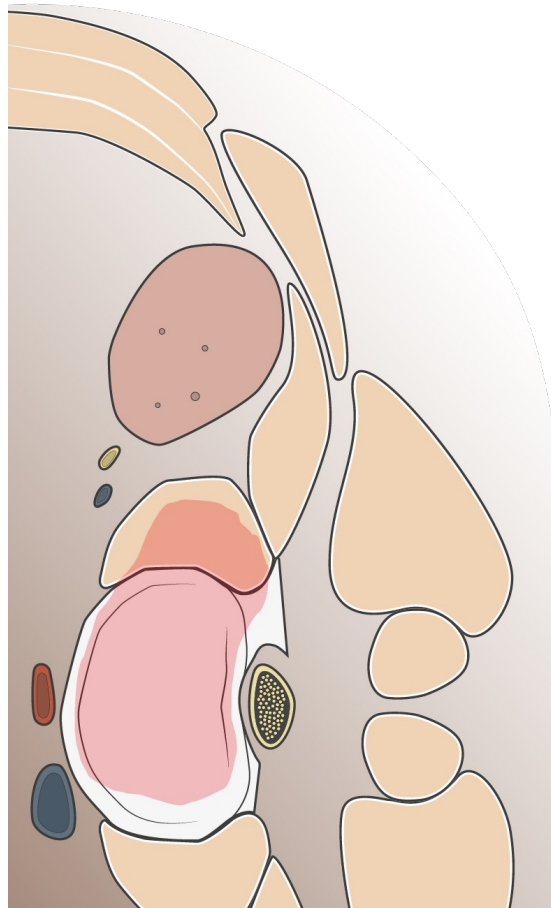
M.A. 52 yo, male – L3 Chordoma



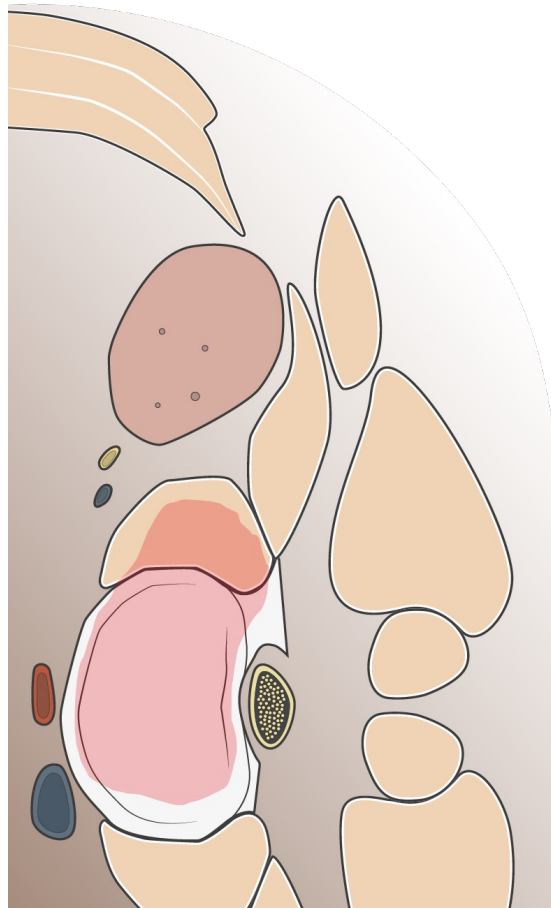
M.A. 52 yo, male – L3 Chordoma



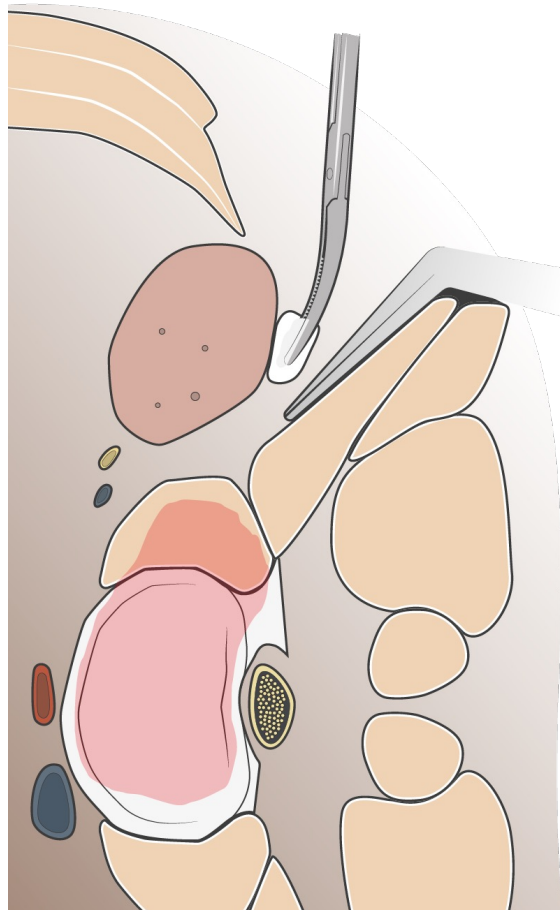
M.A. 52 yo, male – L3 Chordoma



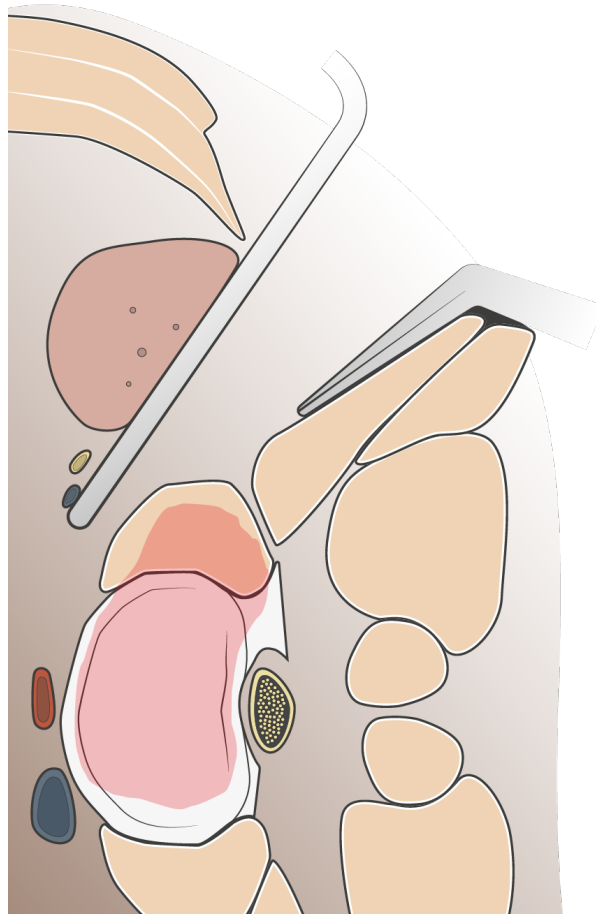
M.A. 52 yo, male – L3 Chordoma



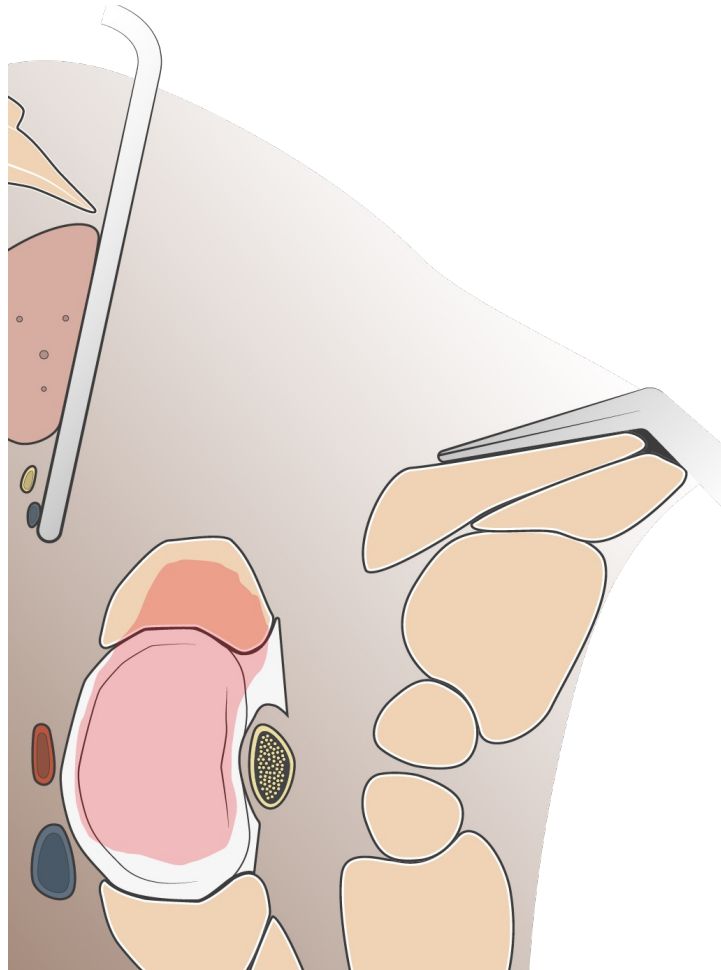
M.A. 52 yo, male – L3 Chordoma




M.A. 52 yo, male – L3 Chordoma




M.A. 52 yo, male – L3 Chordoma



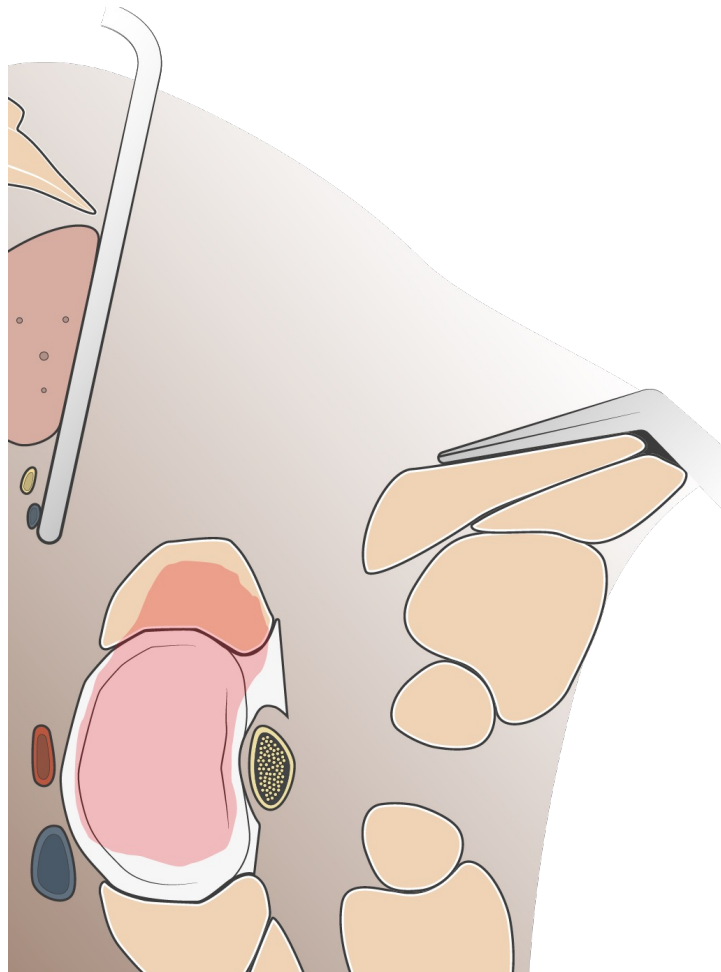
M.A. 52 yo, male – L3 Chordoma



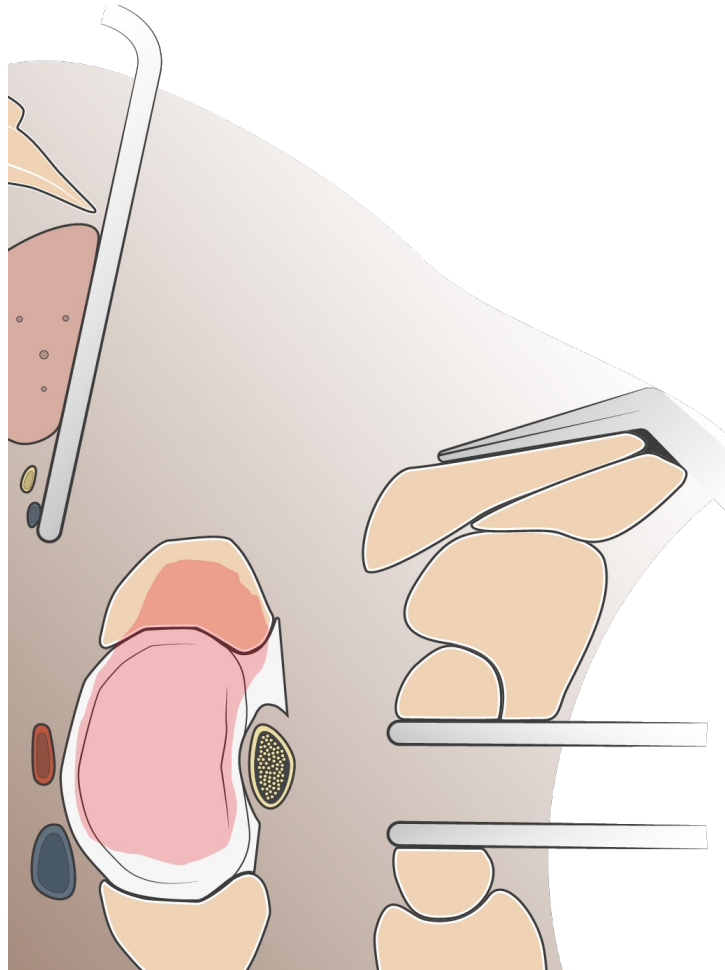
+



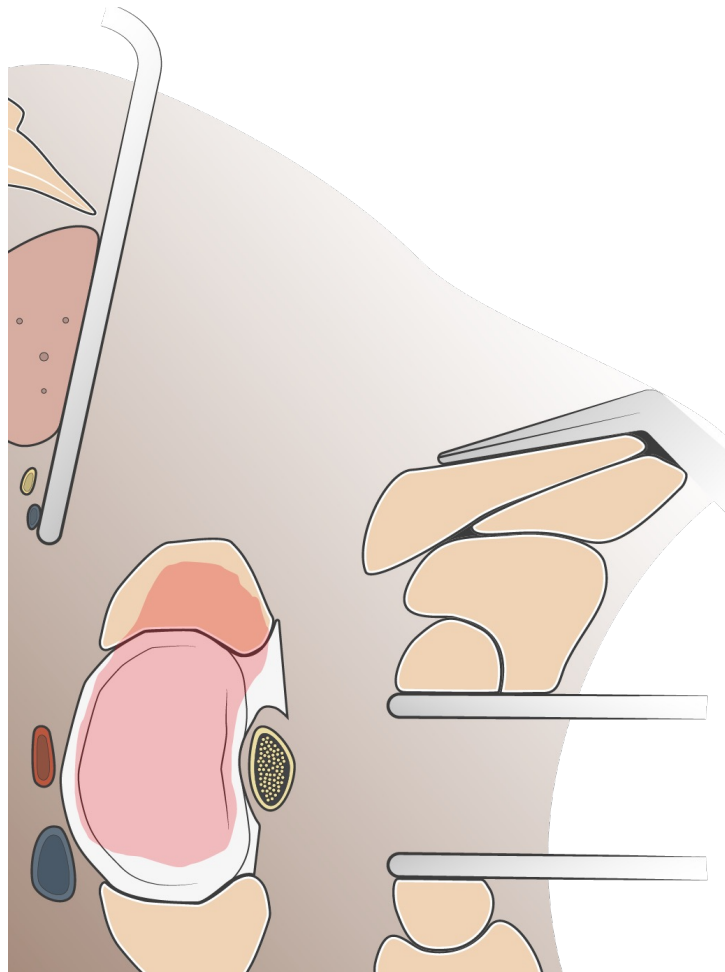
M.A. 52 yo, male – L3 Chordoma



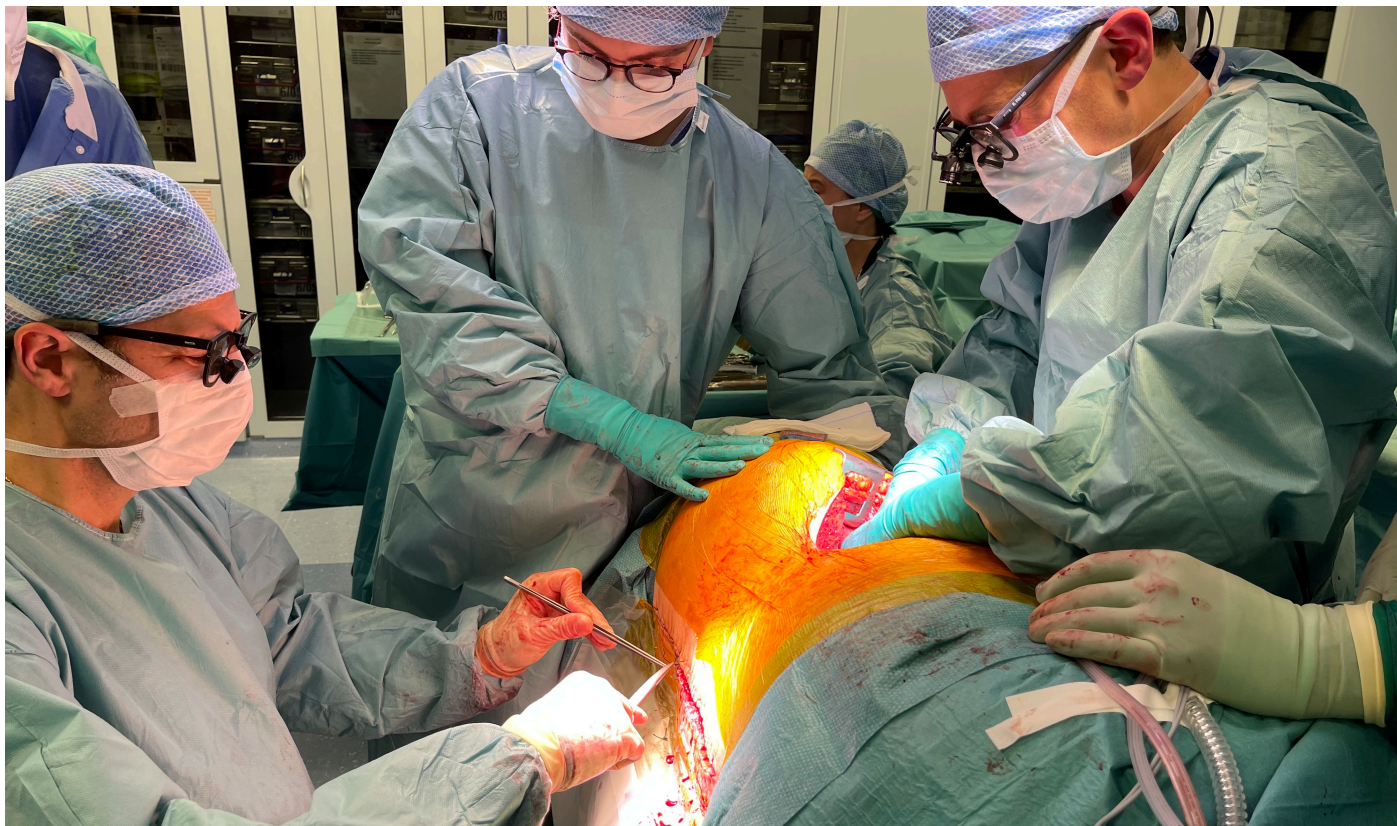M.A. 52 yo, male – L3 Chordoma



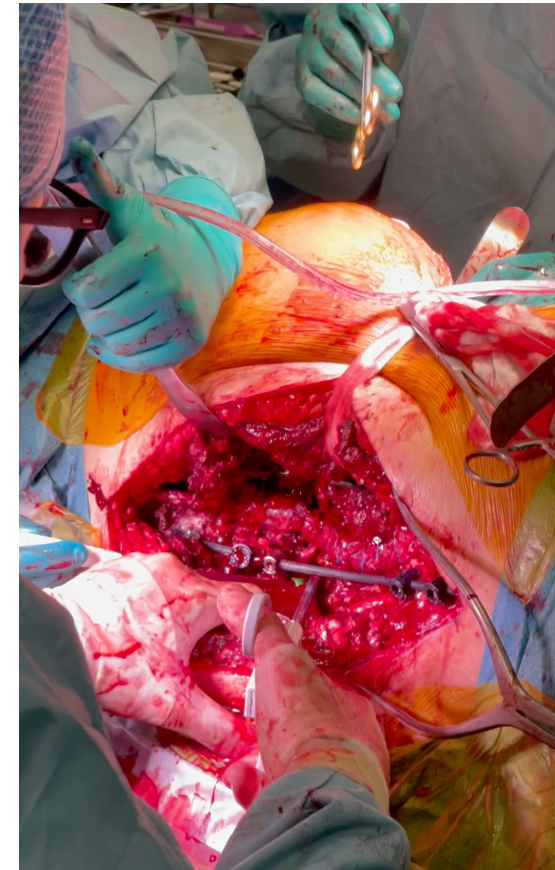
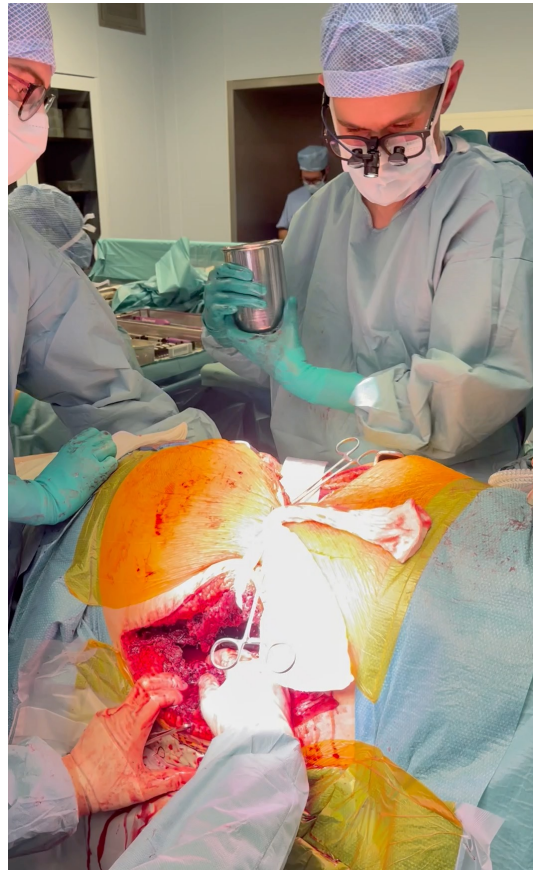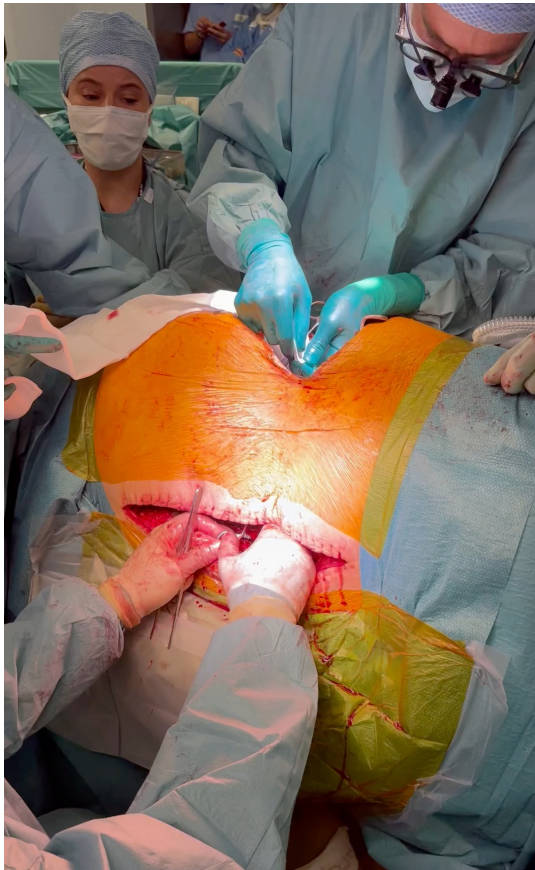
M.A. 52 yo, male – L3 Chordoma



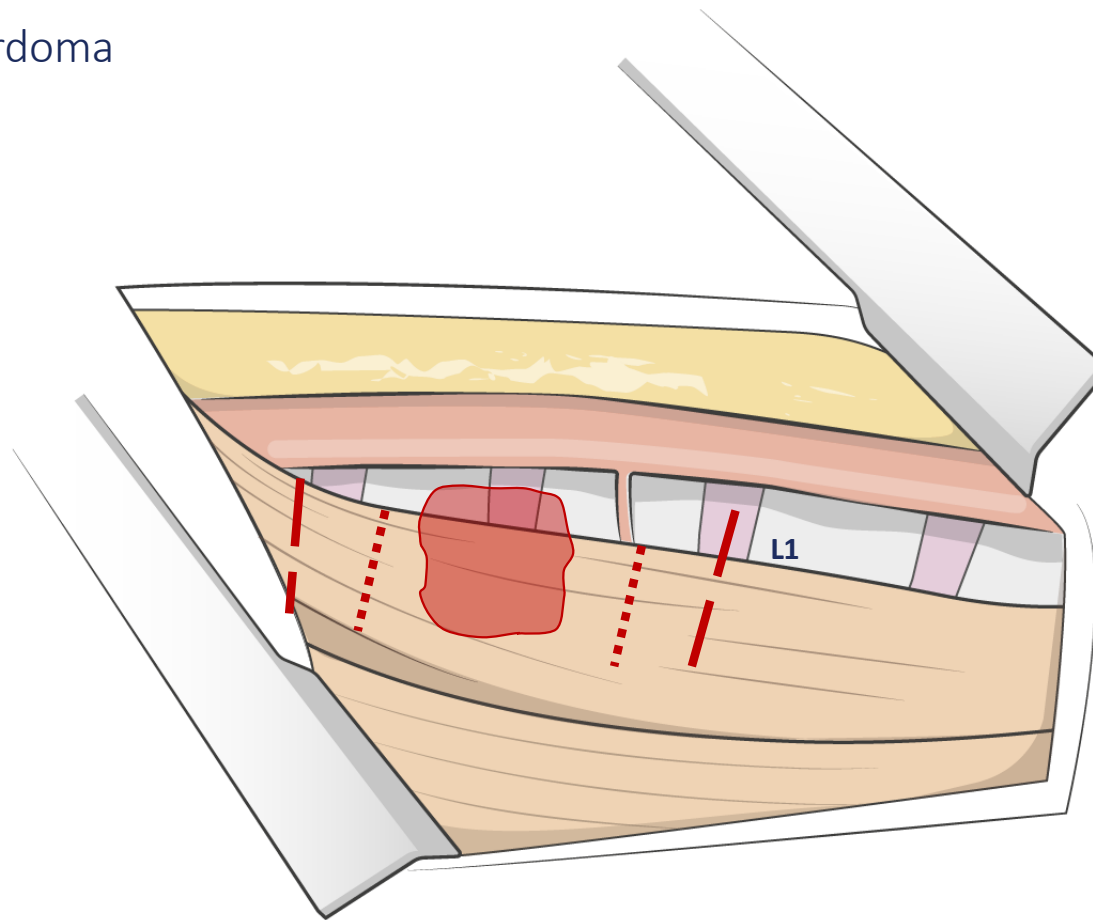
M.A. 52 yo, male – L3 Chordoma



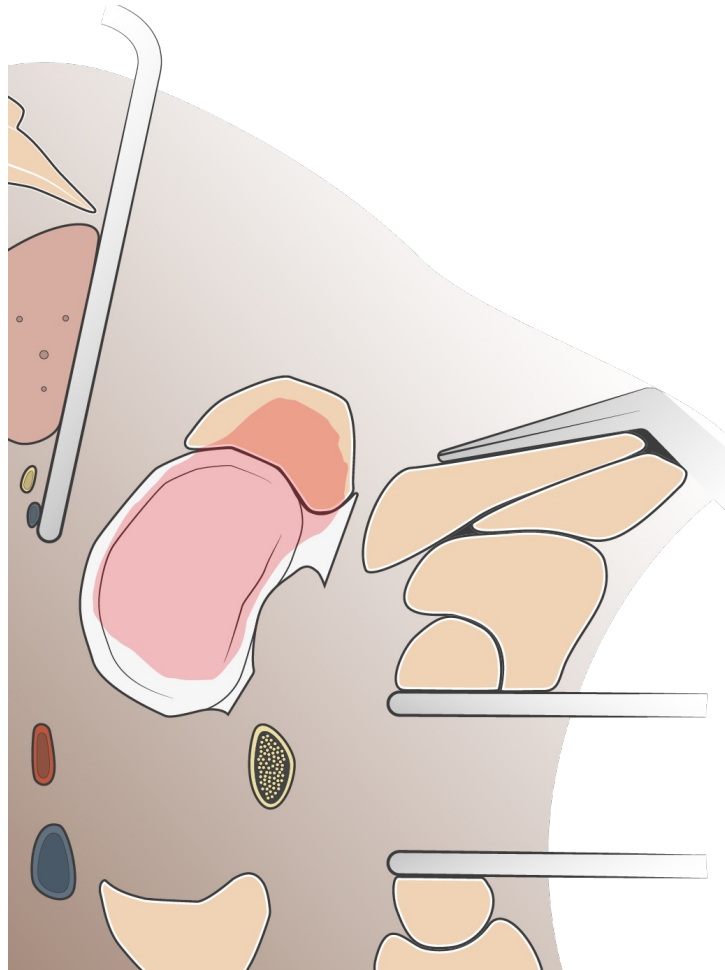
M.A. 52 yo, male – L3 Chordoma



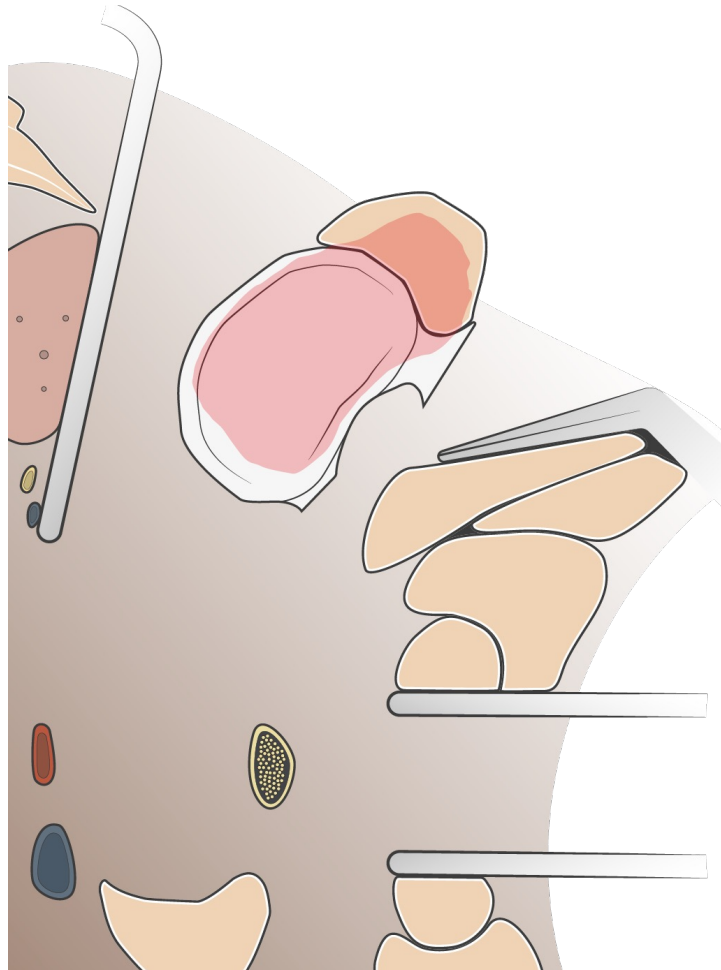
M.A. 52 yo, male – L3 Chordoma



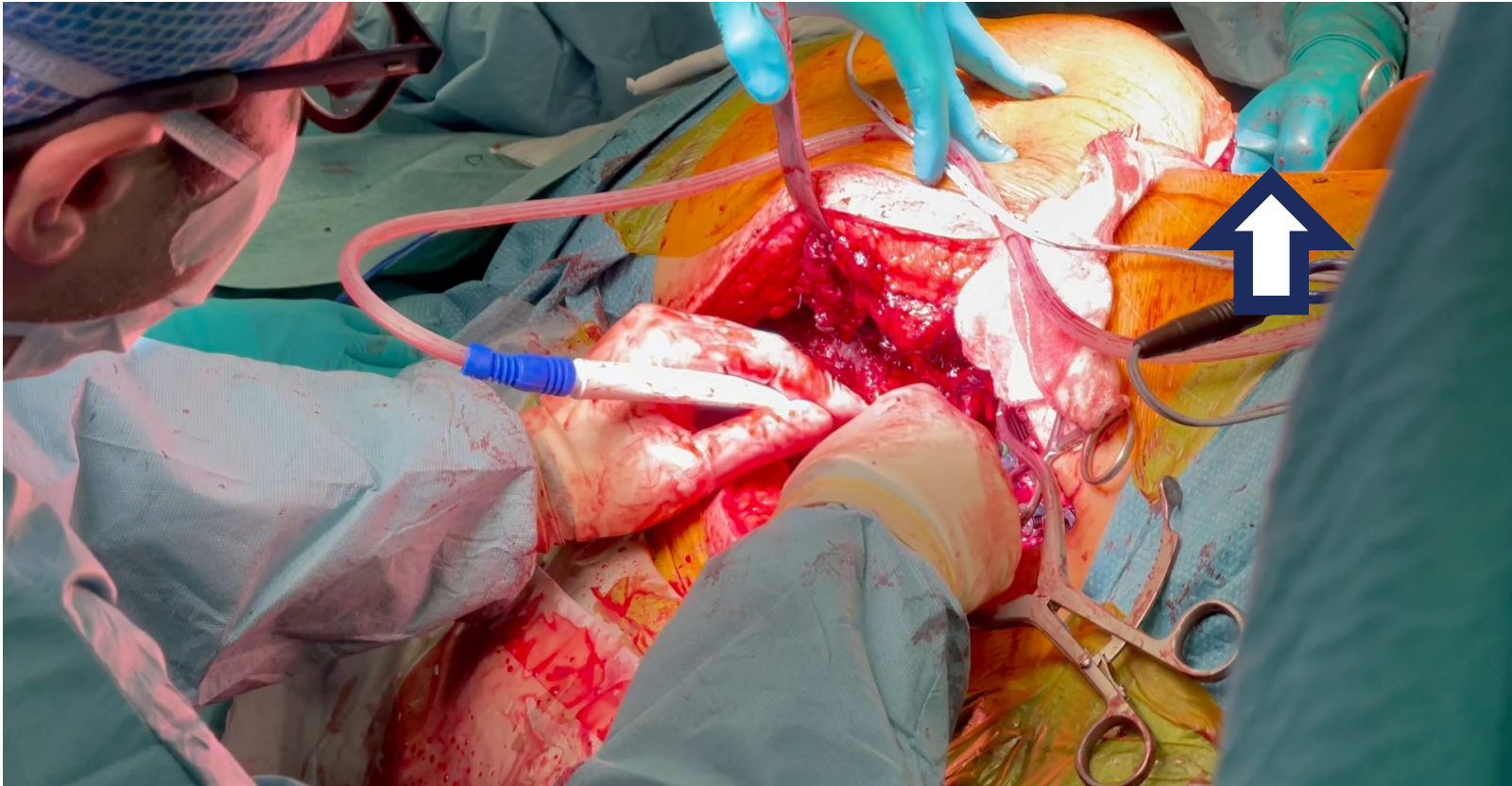
M.A. 52 yo, male – L3 Chordoma



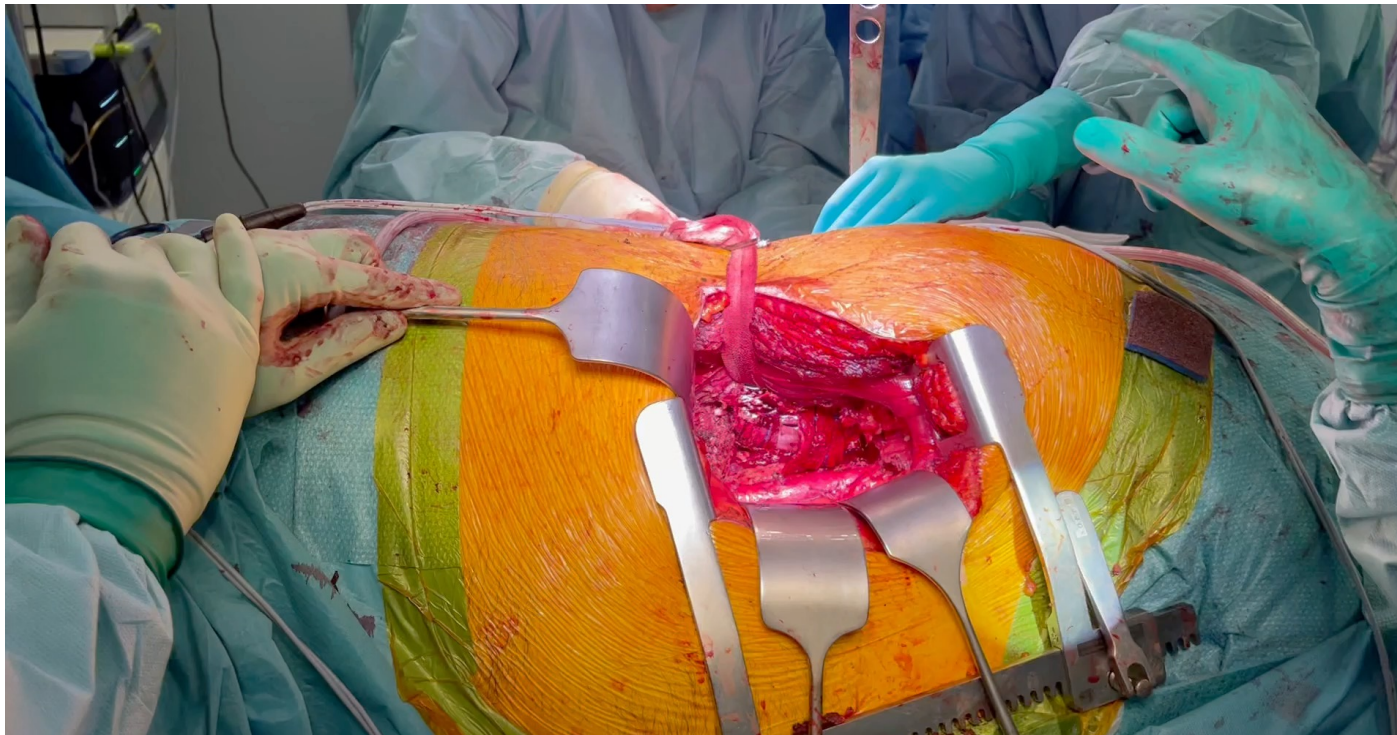
M.A. 52 yo, male – L3 Chordoma



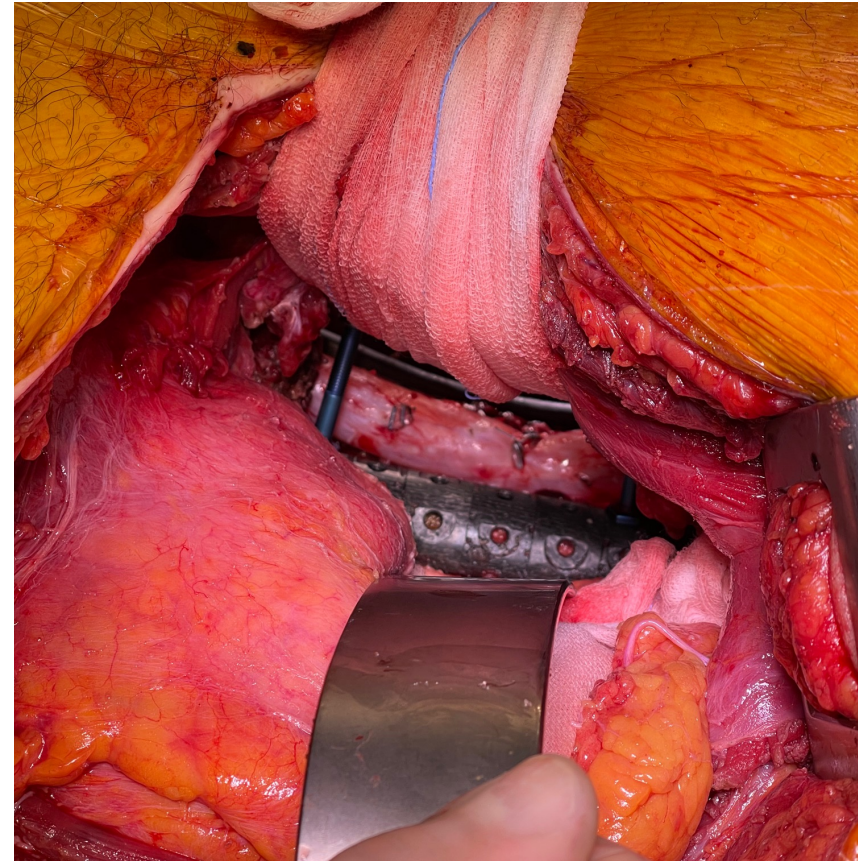
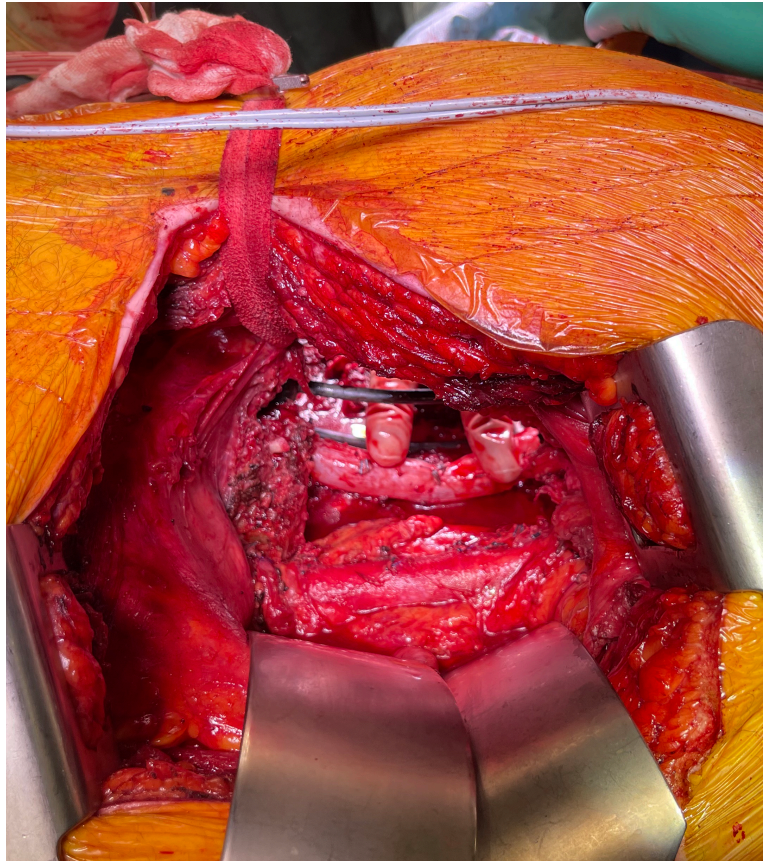
M.A. 52 yo, male – L3 Chordoma



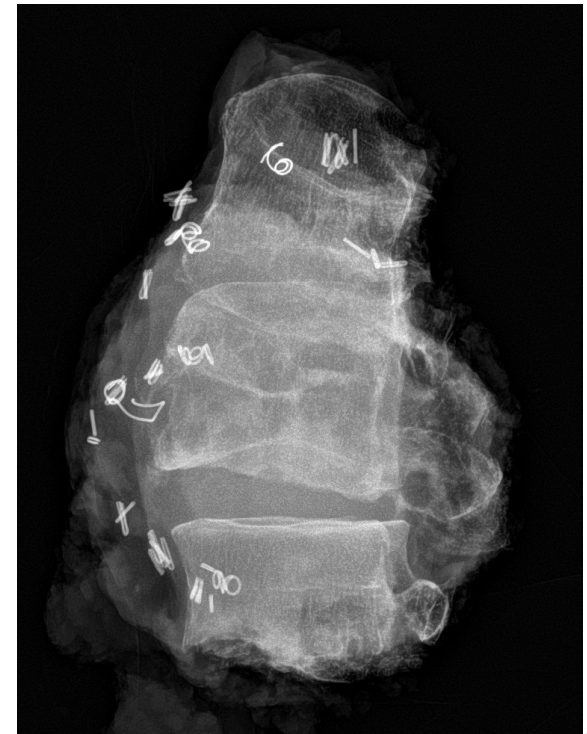
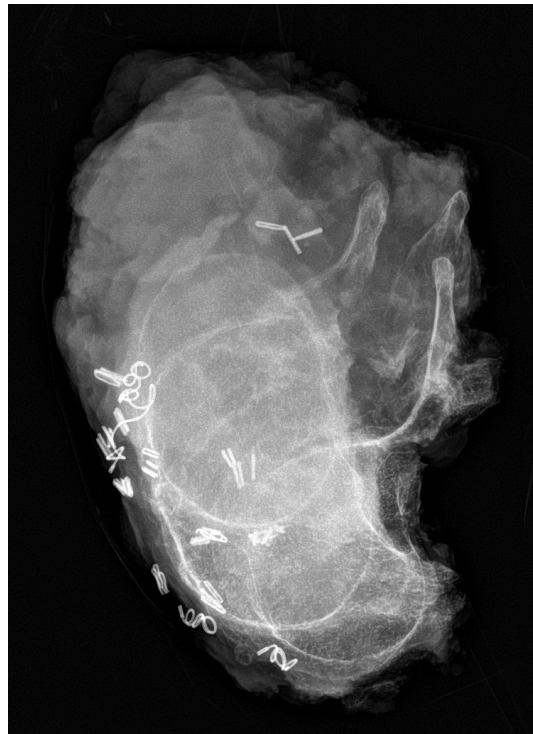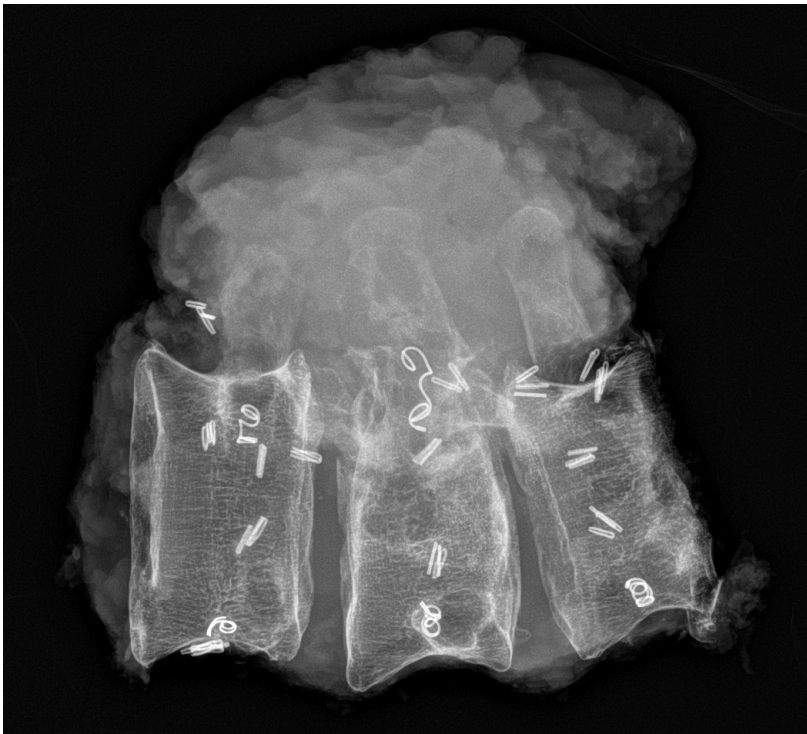
M.A. 52 yo, male – L3 Chordoma



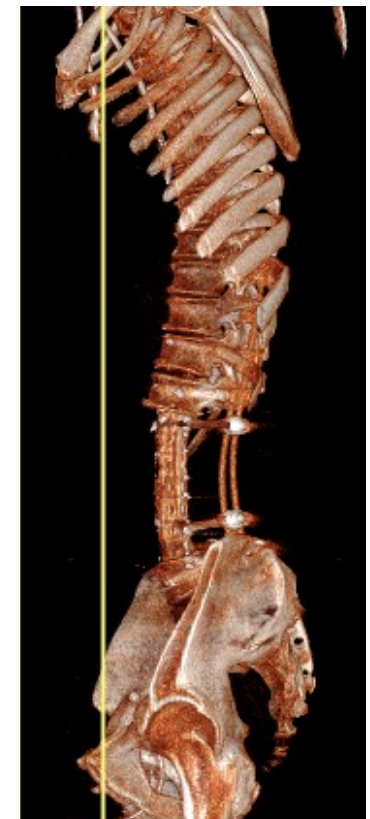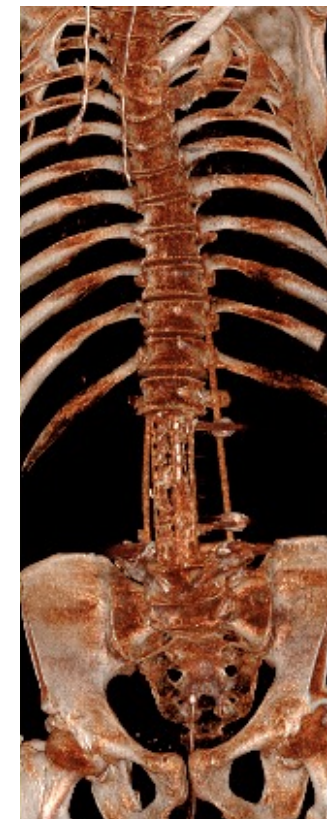
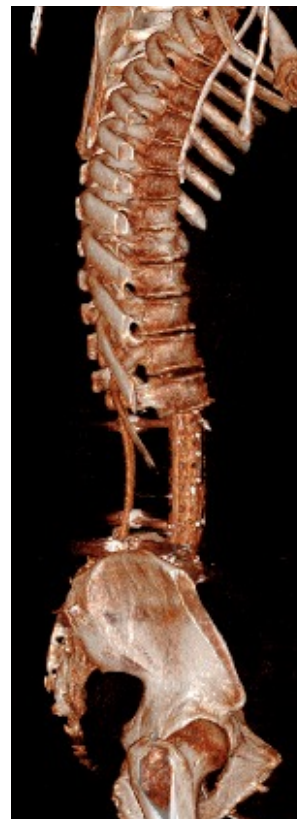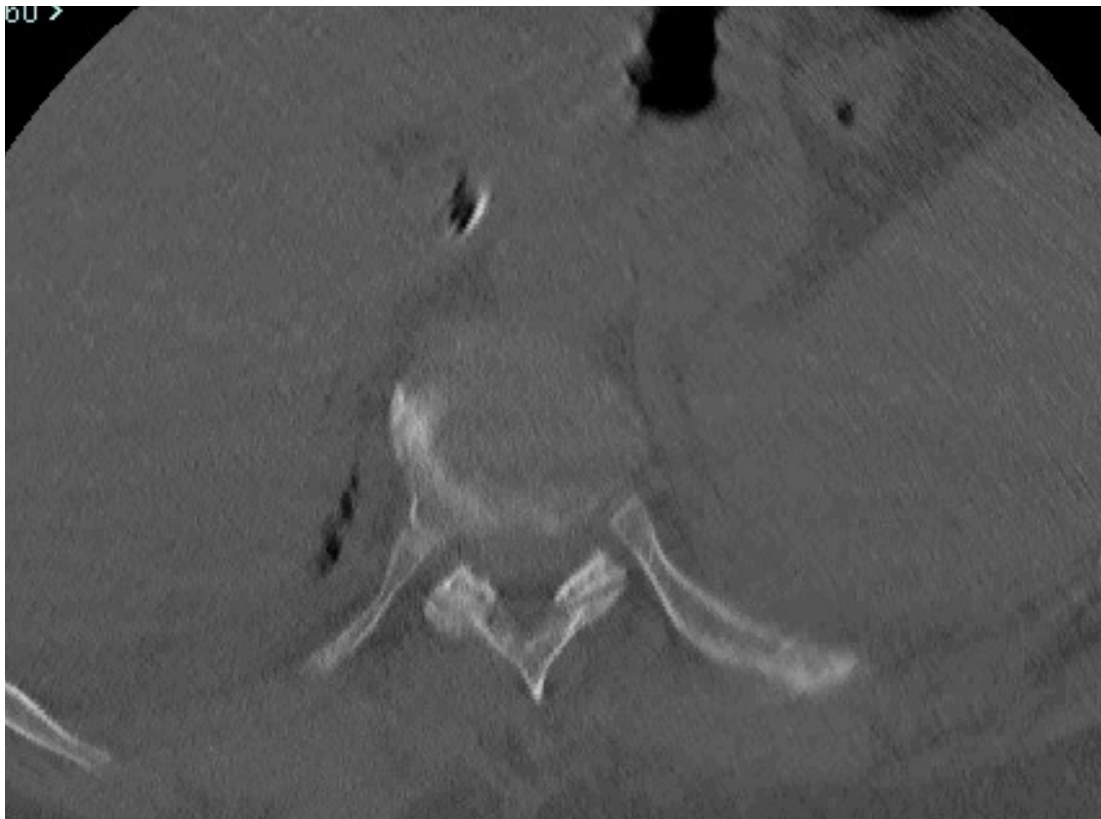M.A. 52 yo, male – L3 Chordoma



M.A. 52 yo, male – L3 Chordoma

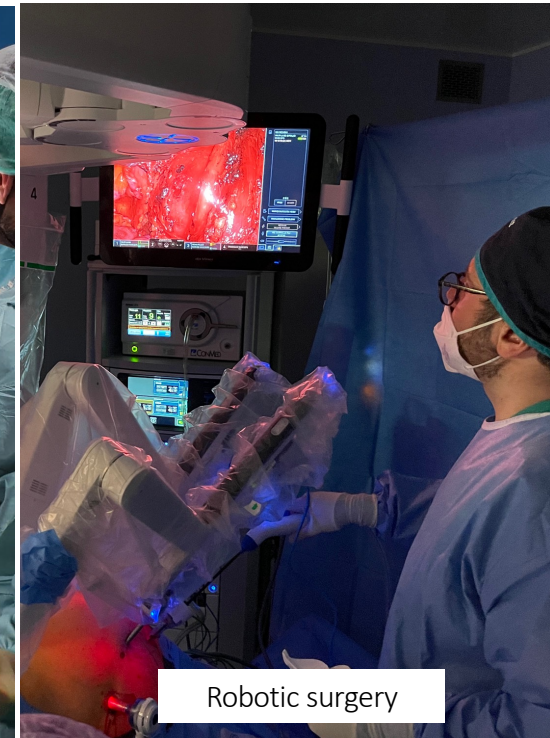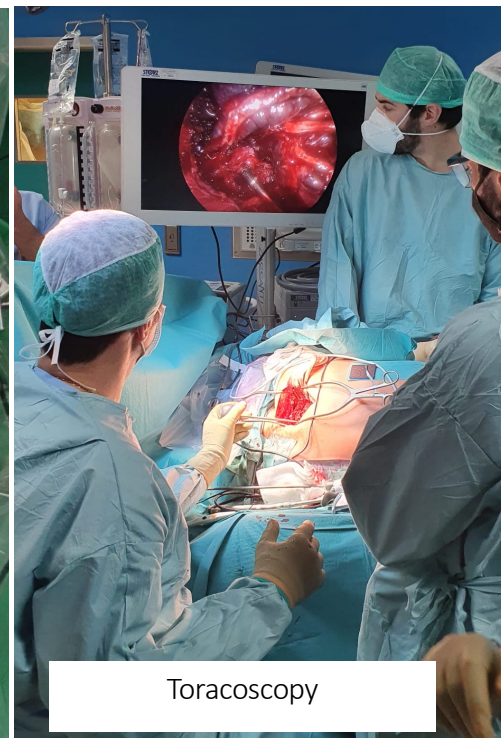
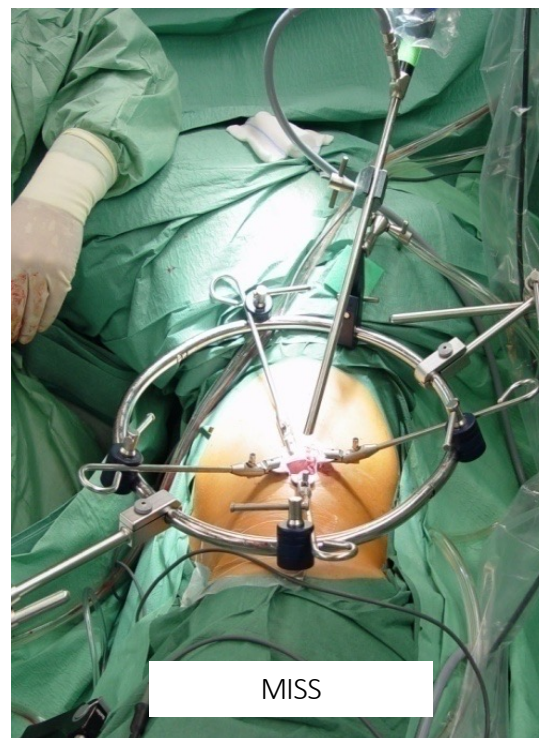
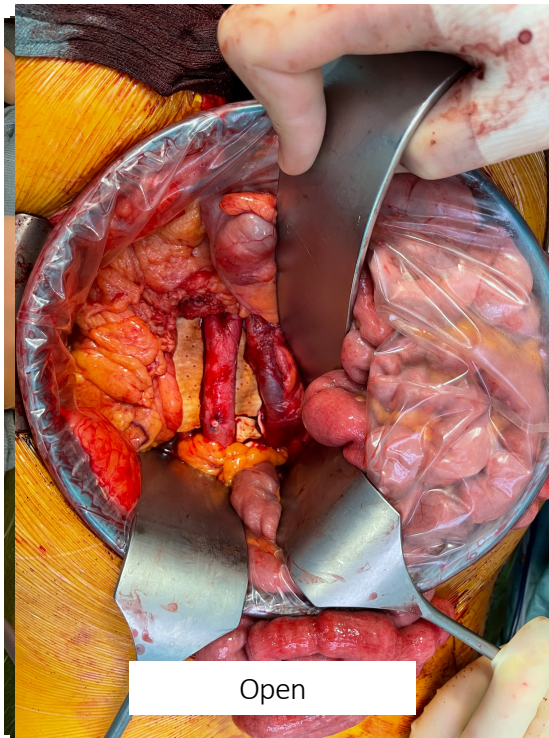


M.A. 52 yo, male – L3 Chordoma



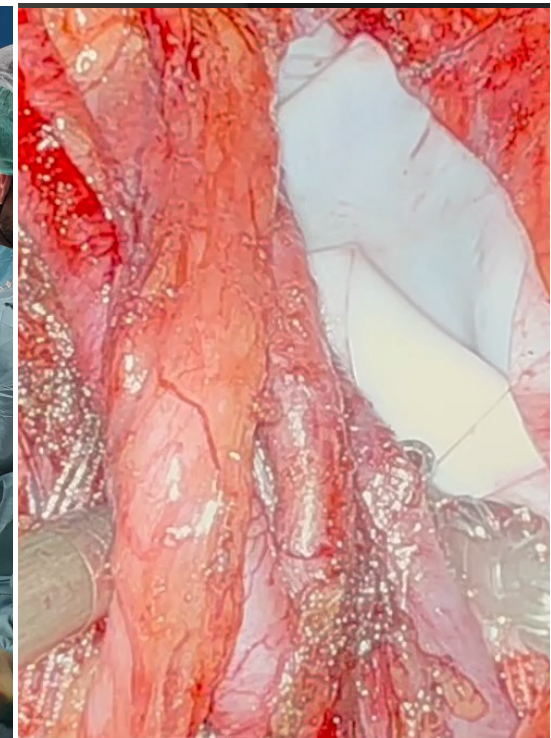
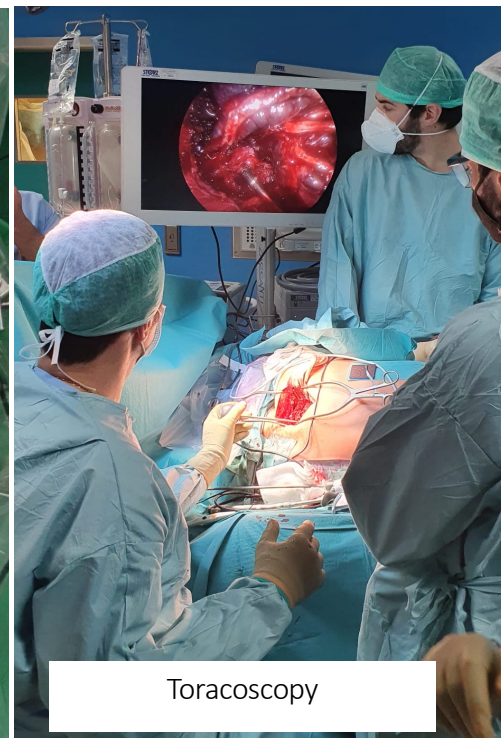
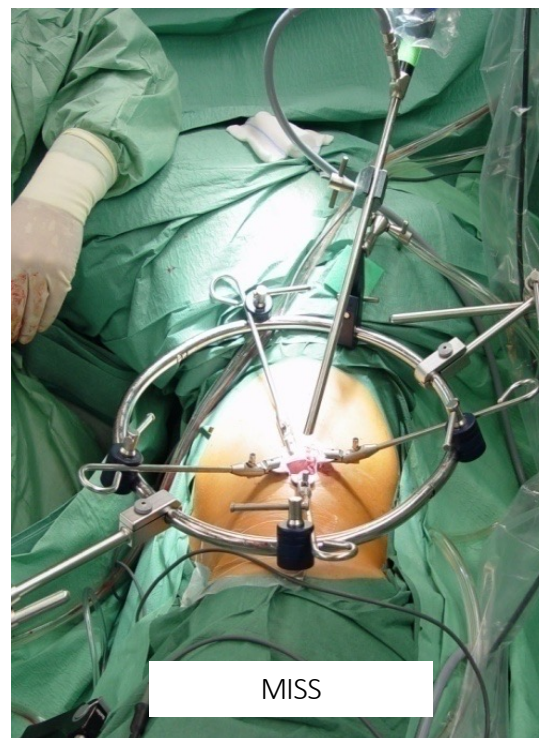
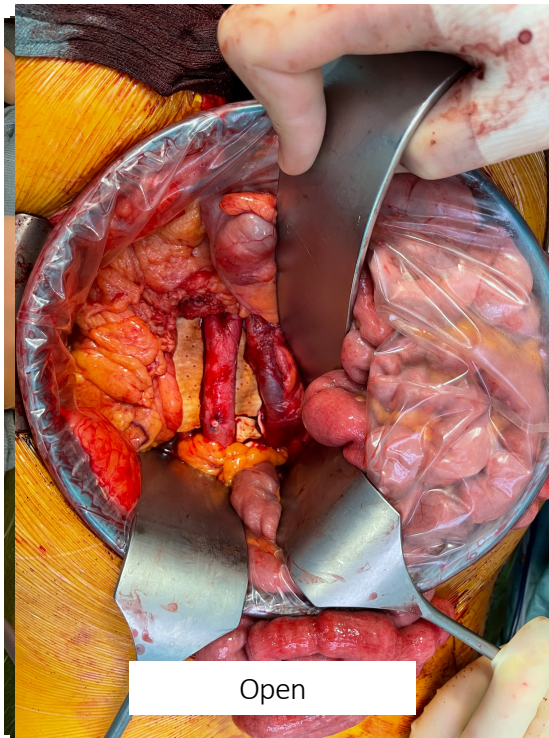
Quando è indicato un doppio approccio...

less is more



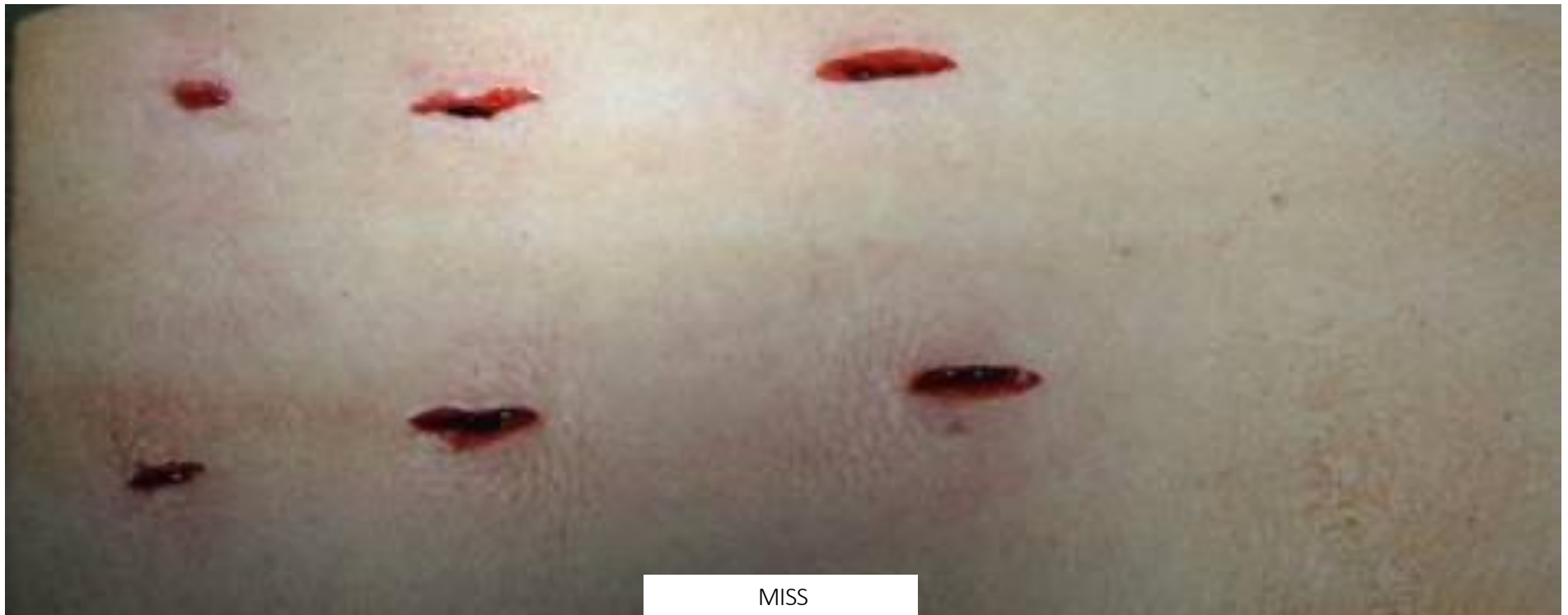Quando è indicato un doppio approccio...

less is more



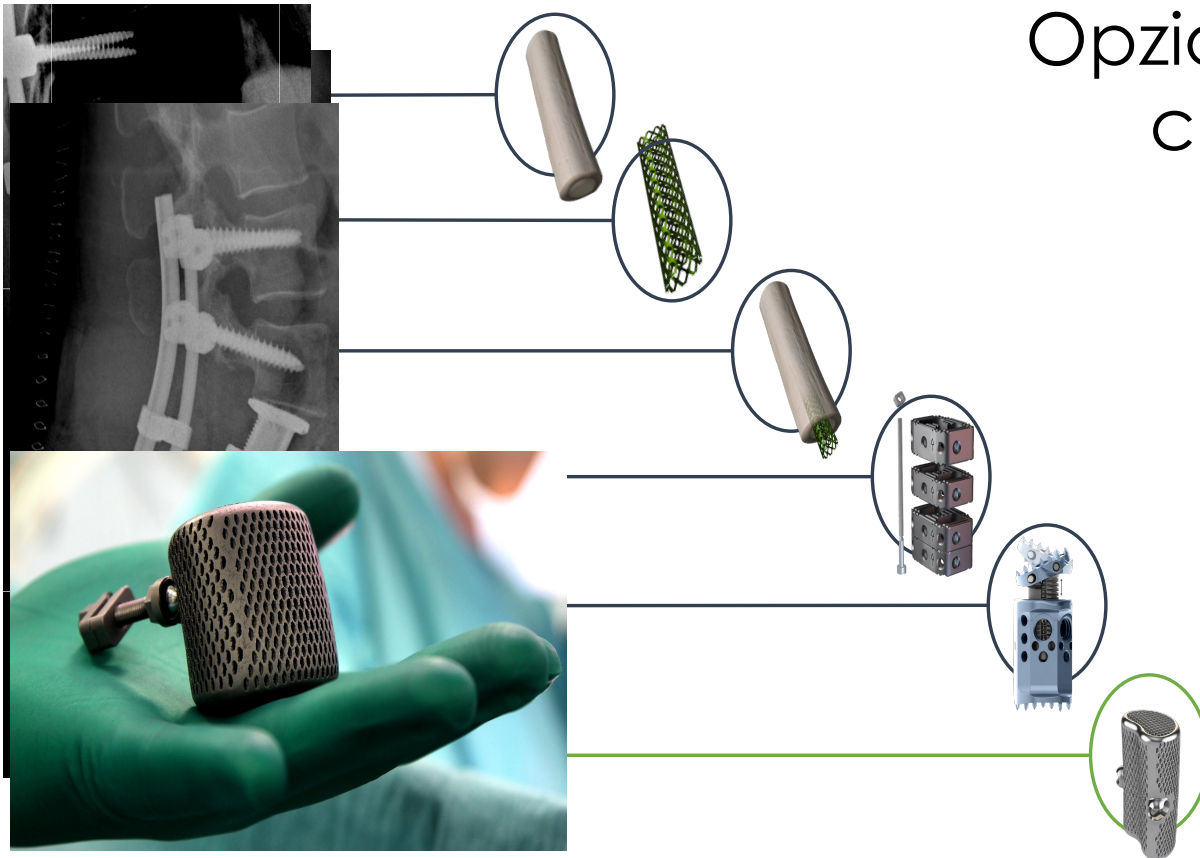
Quando è indicato un doppio approccio...

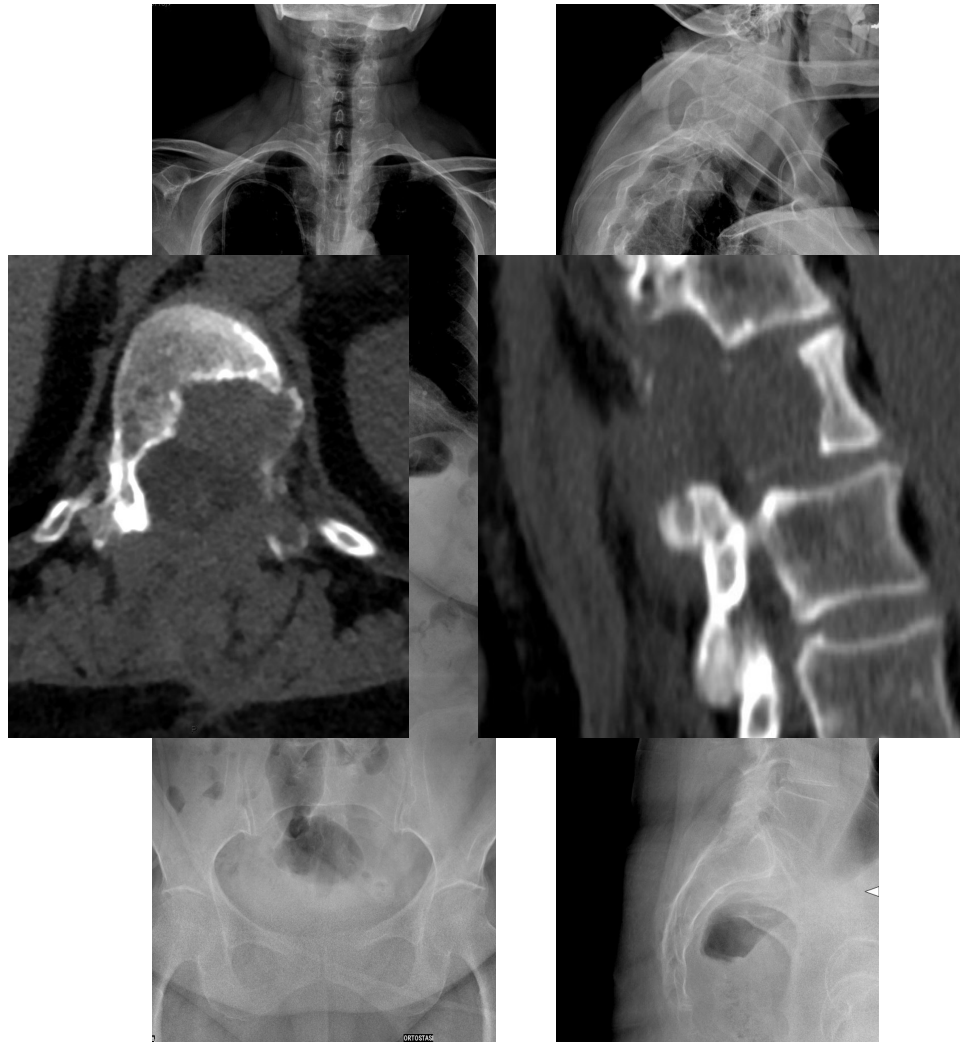less is more







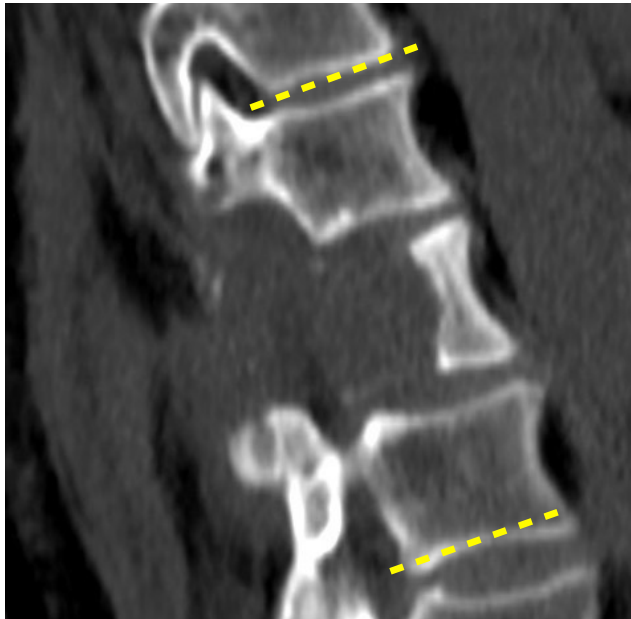
Opzioni ricostruttive della colonna anteriore



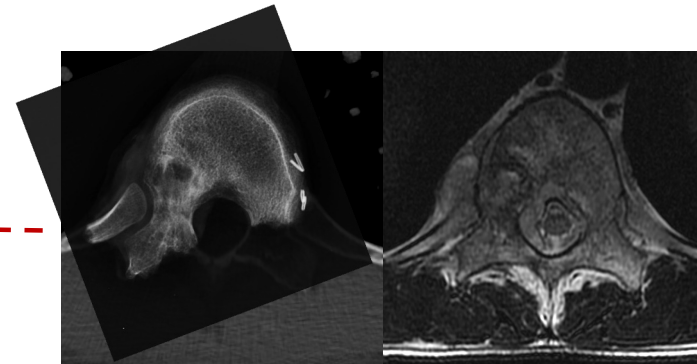
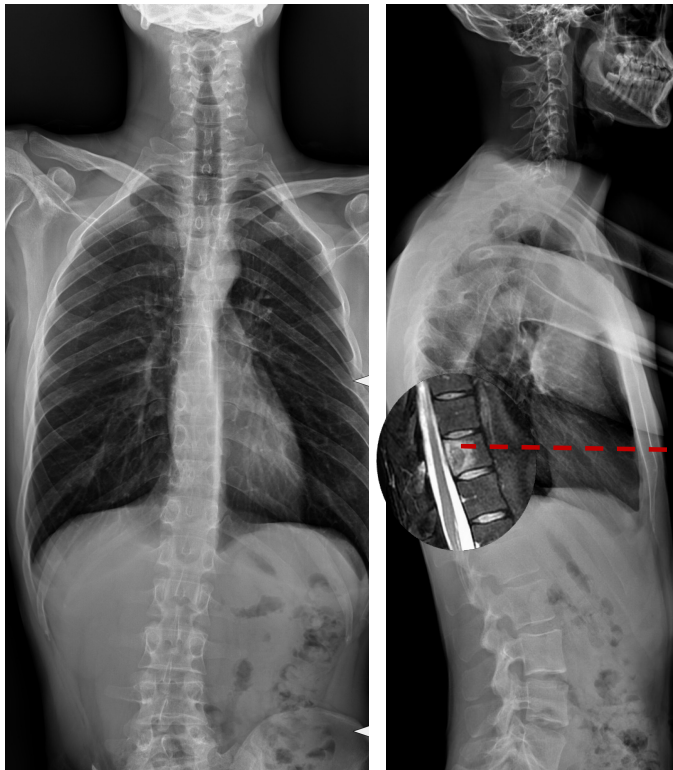


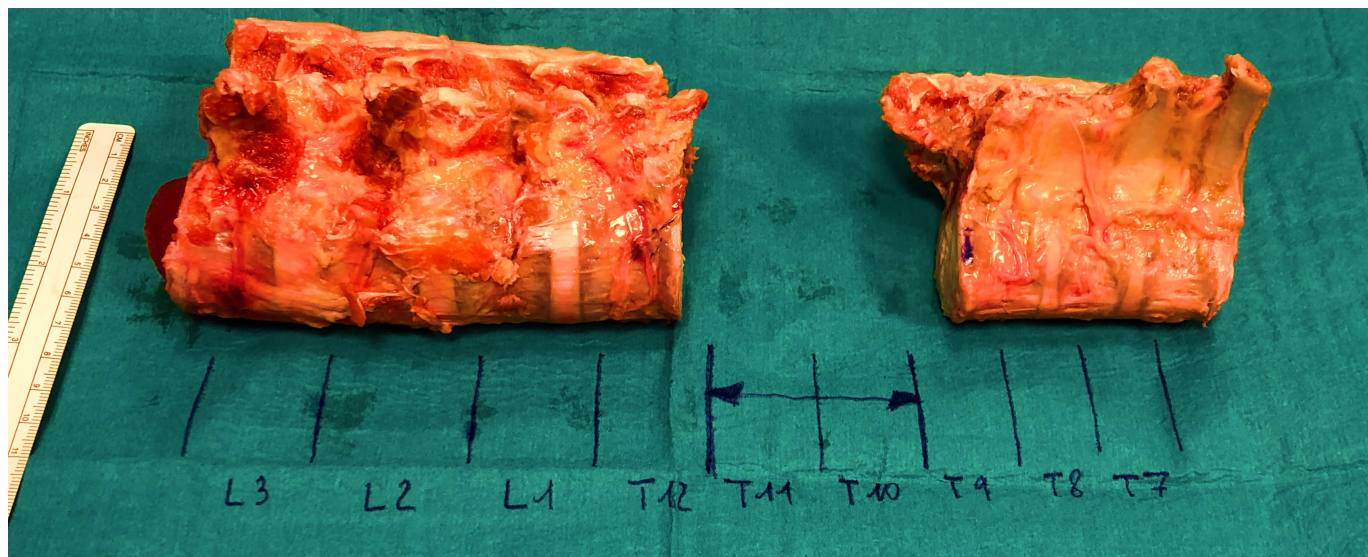
Caterina, 65 anni,
osteosarcoma
fibroblastico di
T12

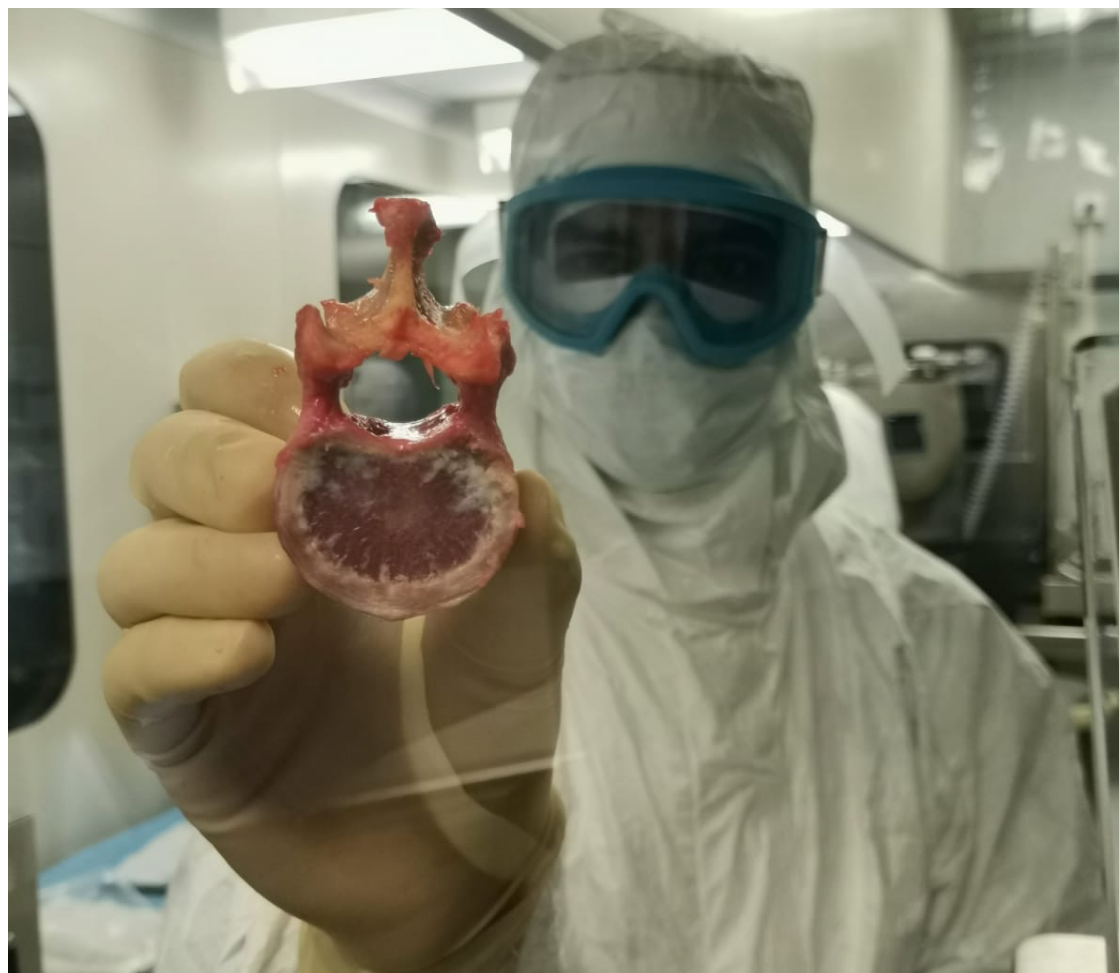



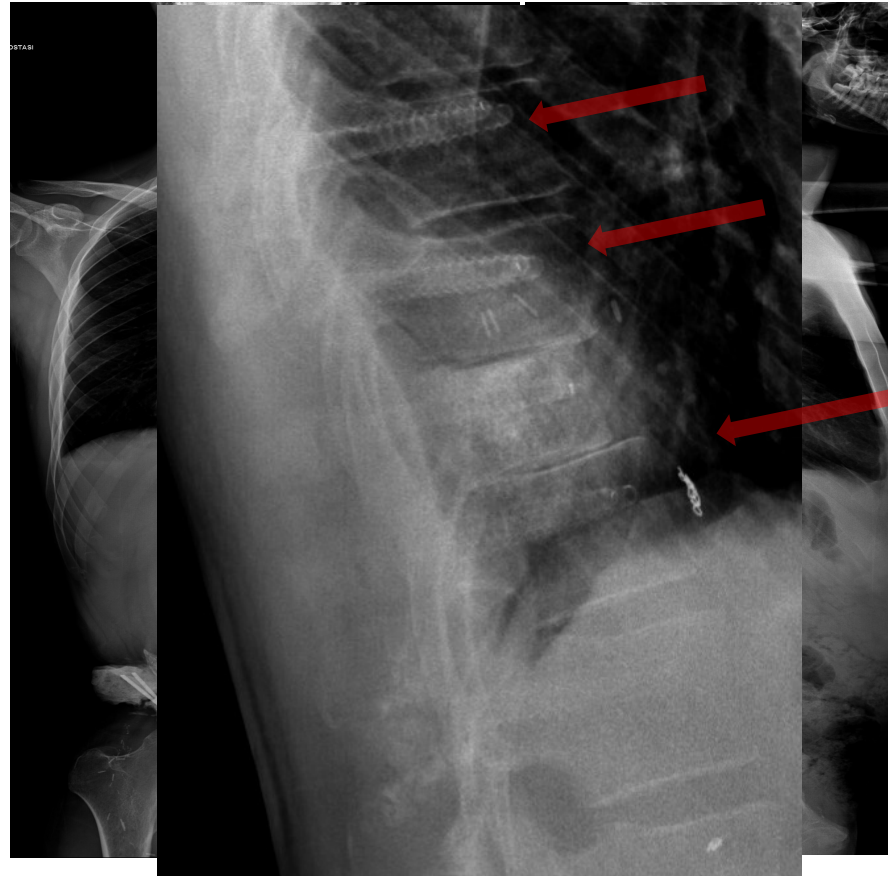
Tommaso, 27 anni ,
sarcoma di Ewing di
T11





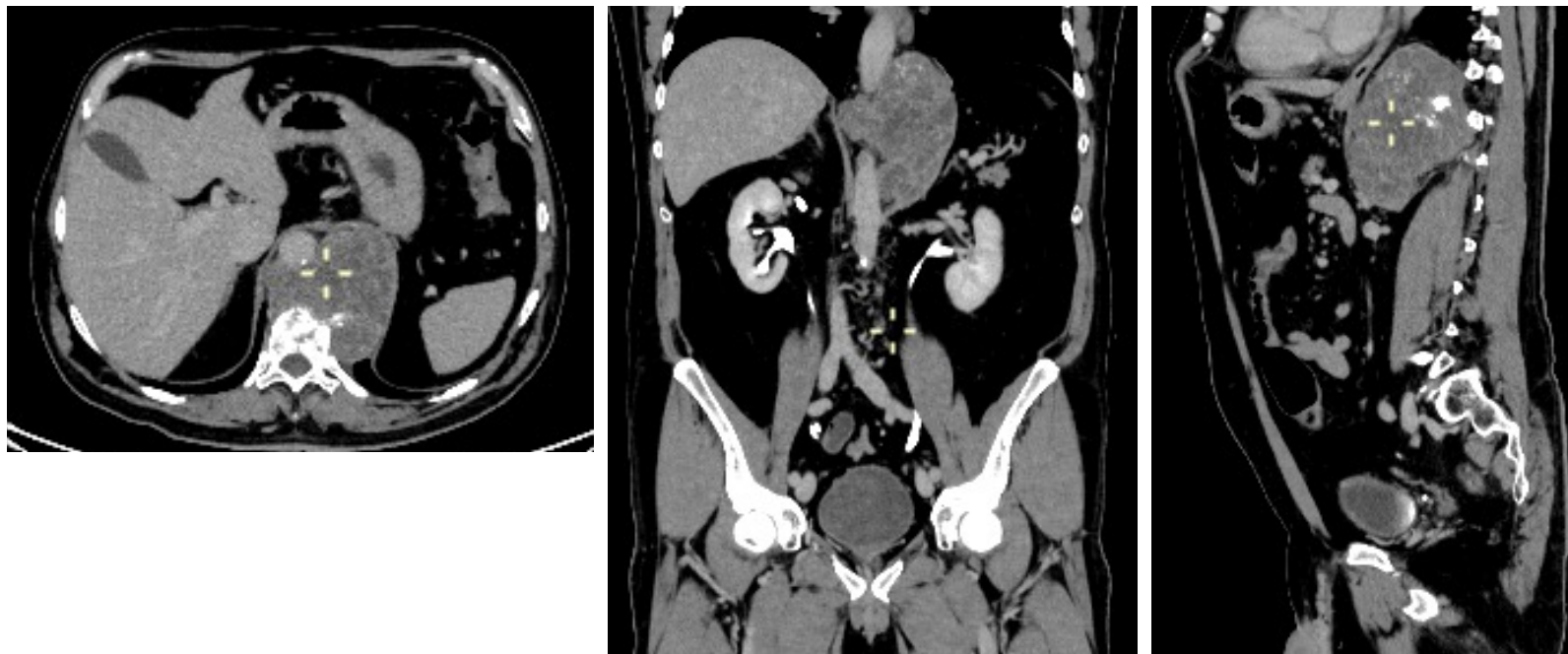


Trapianto di vertebra

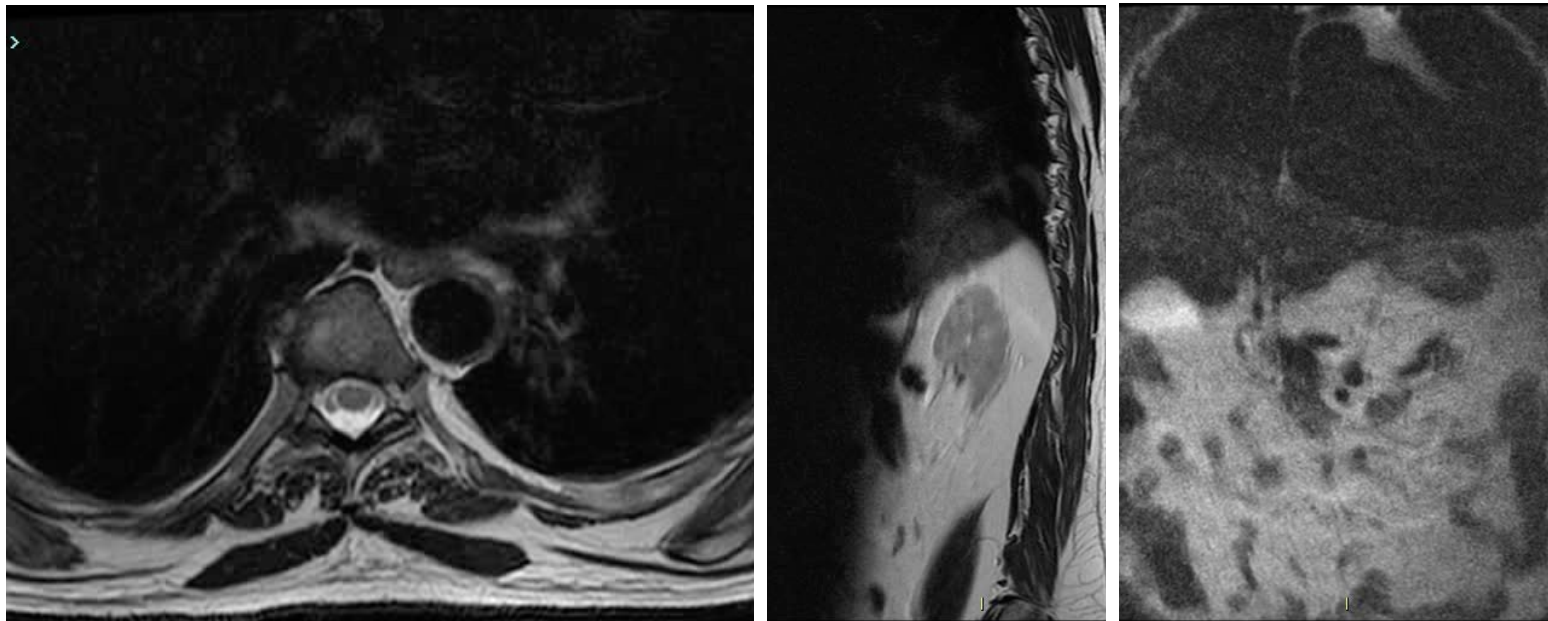


Trapianto di vertebra

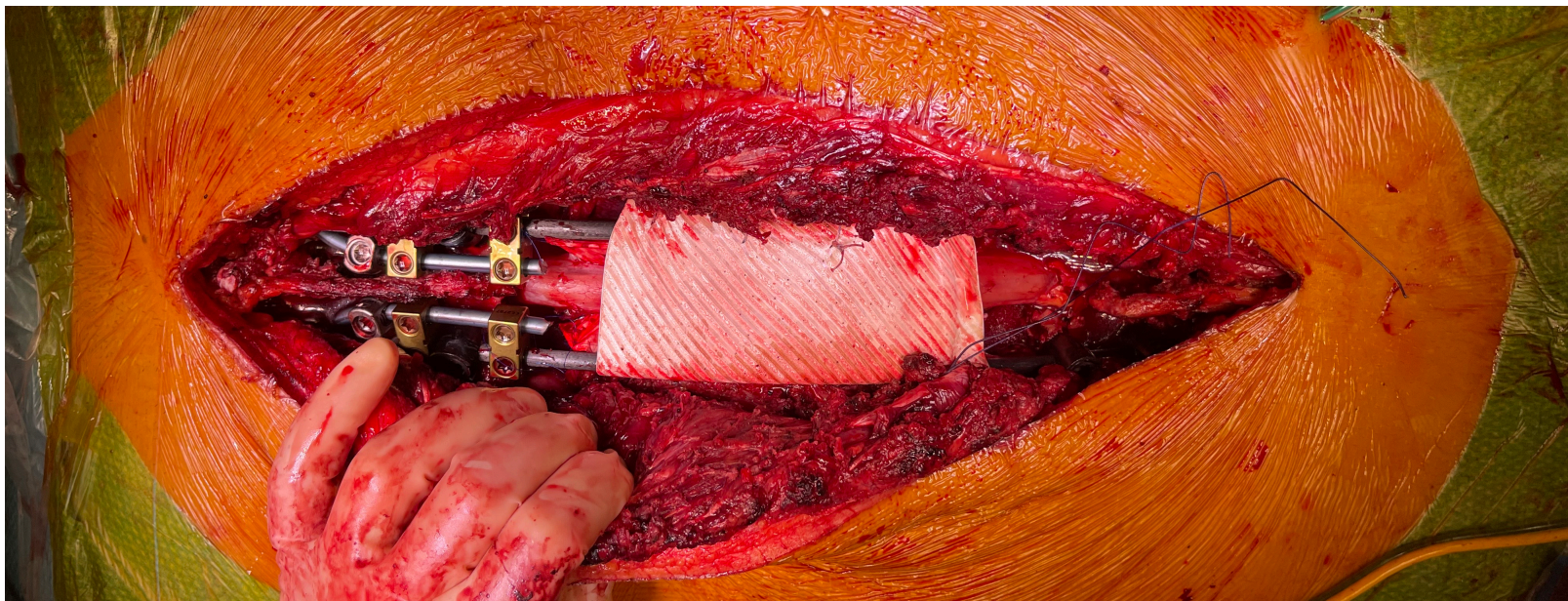
P.S.G. 58 yo, male – T8, T9, T10, T11, T12, L1 Chordoma



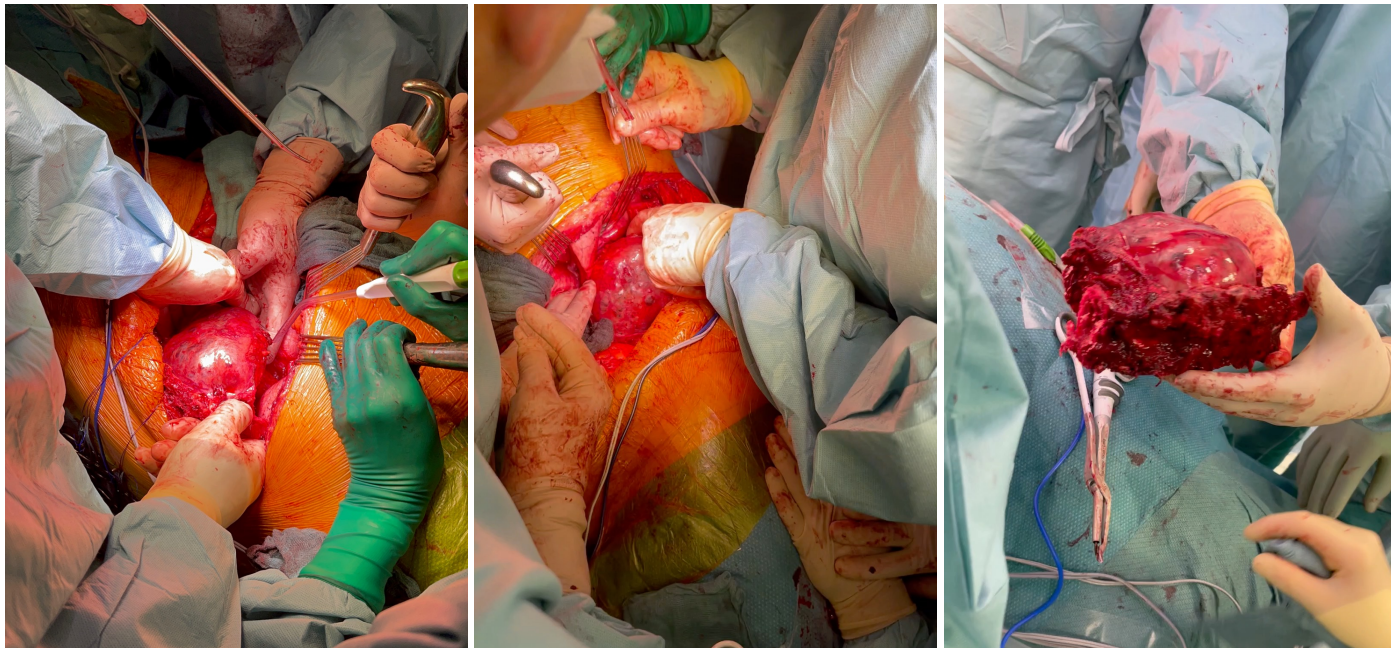
P.S.G. 58 yo, male – T8, T9, T10, T11, T12, L1 Chordoma



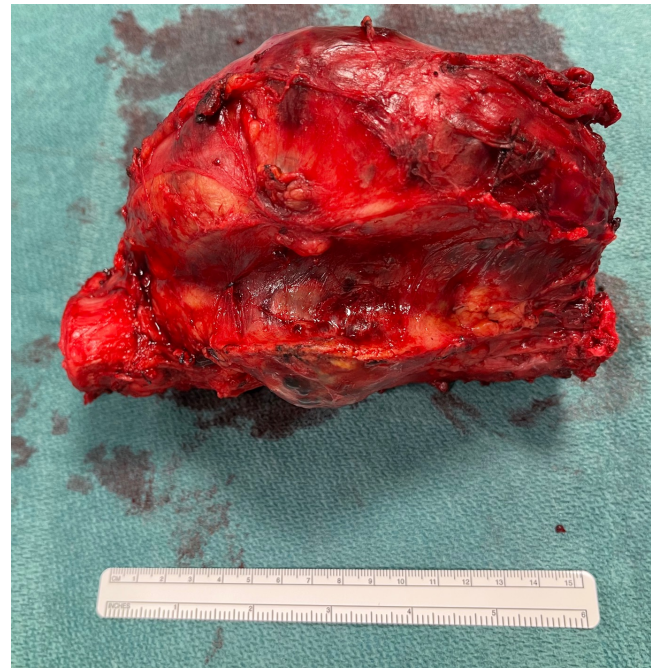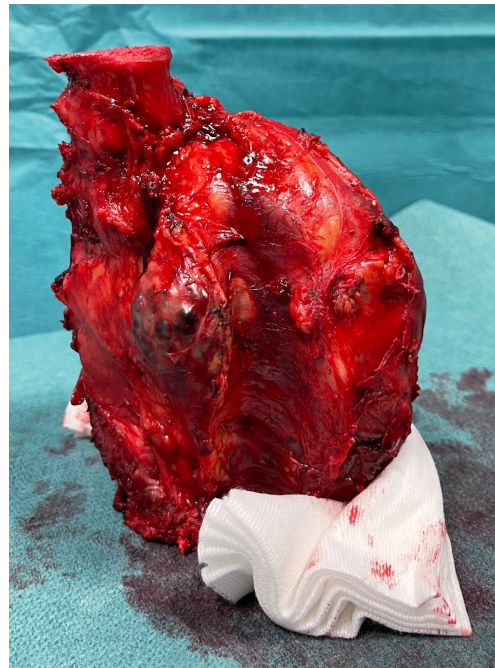
P.S.G. 58 yo, male – T8, T9, T10, T11, T12, L1 Chordoma



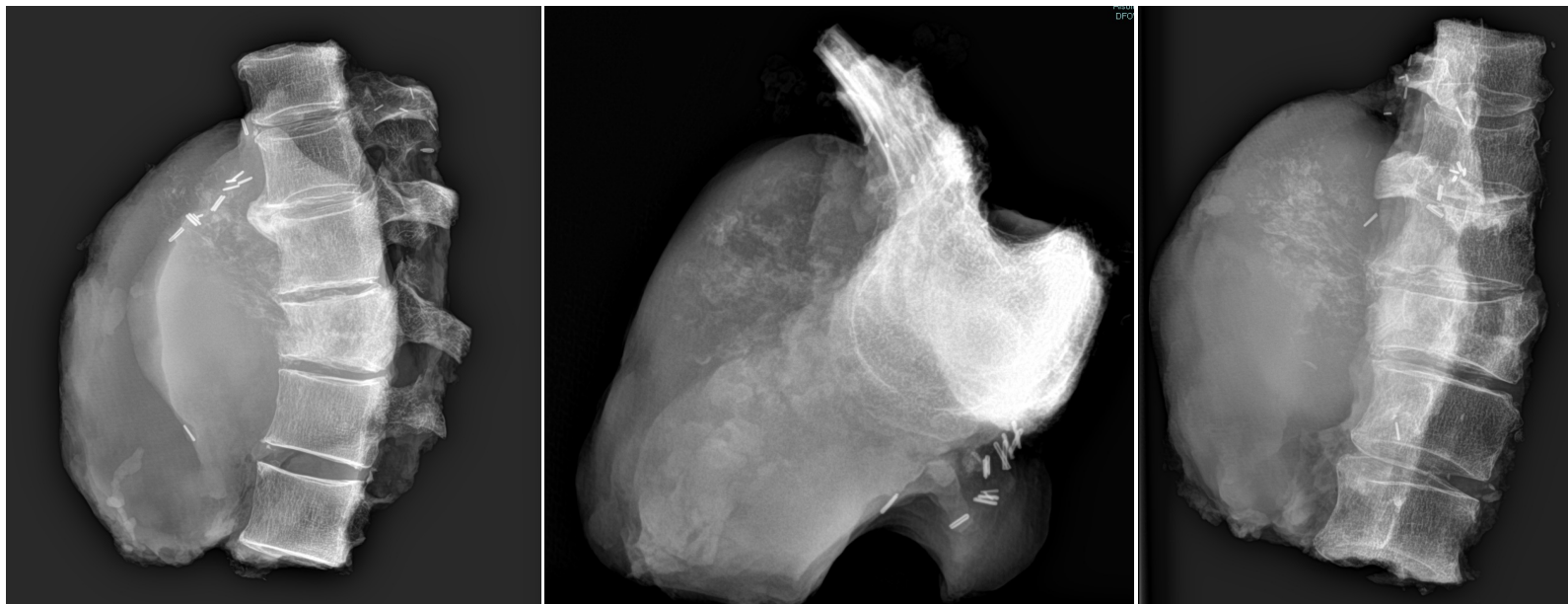
P.S.G. 58 yo, male – T8, T9, T10, T11, T12, L1 Chordoma



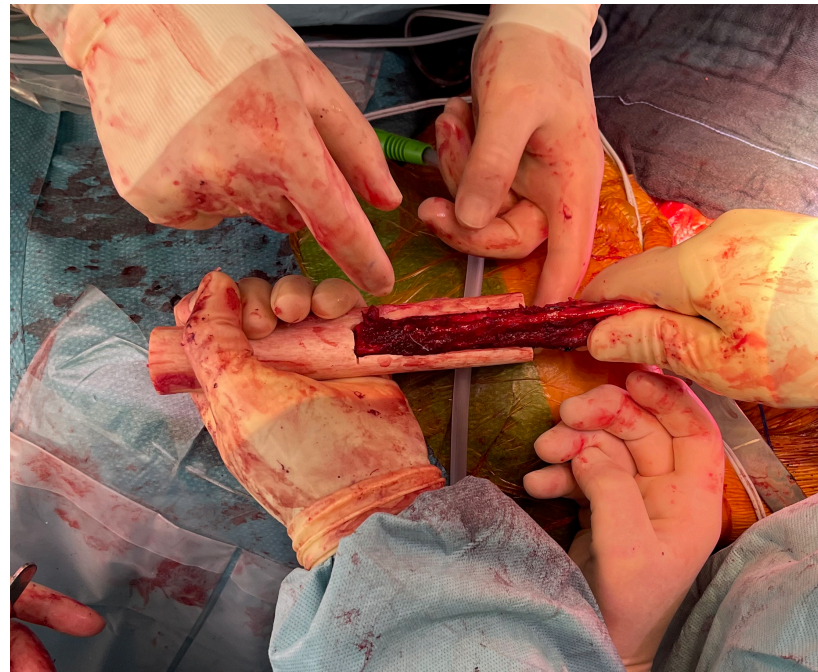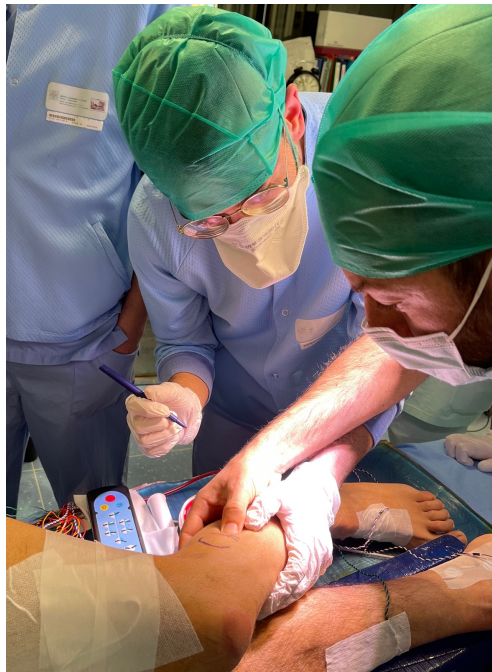P.S.G. 58 yo, male – T8, T9, T10, T11, T12, L1 Chordoma



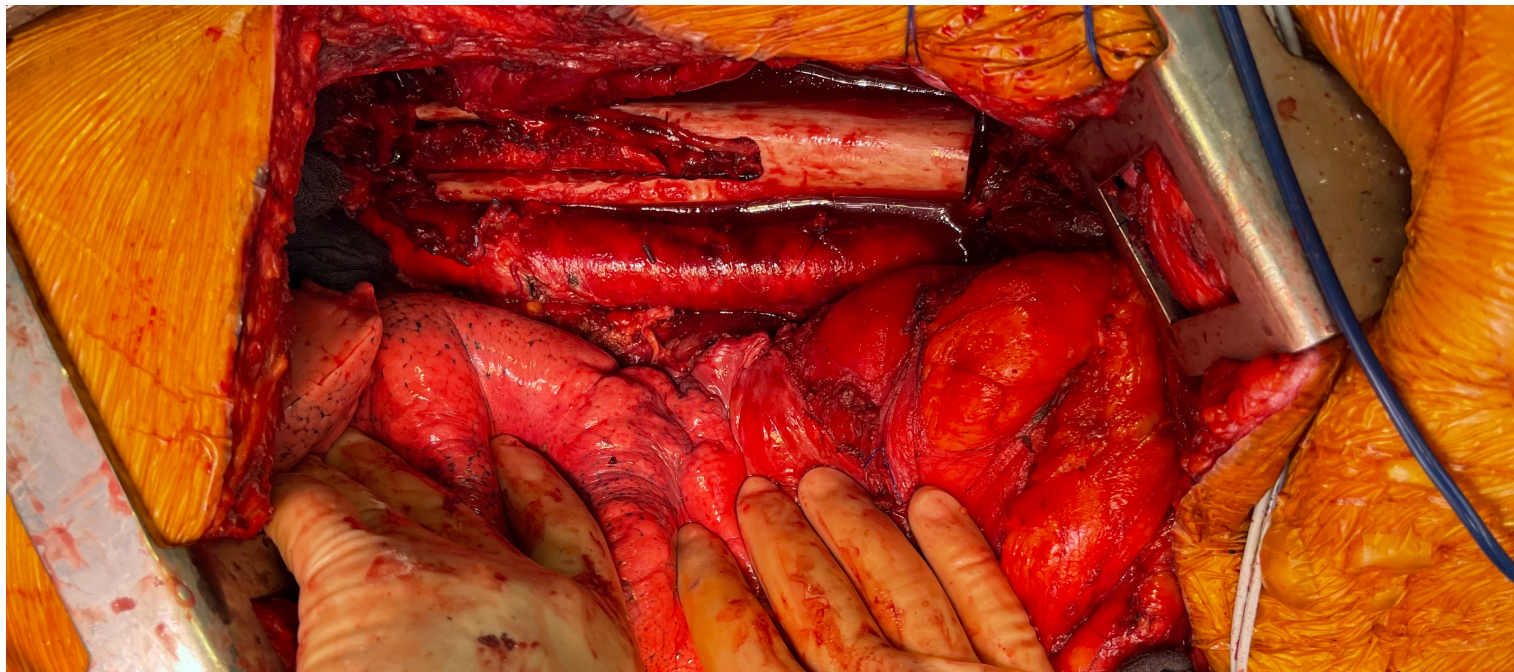P.S.G. 58 yo, male – T8, T9, T10, T11, T12, L1 Chordoma



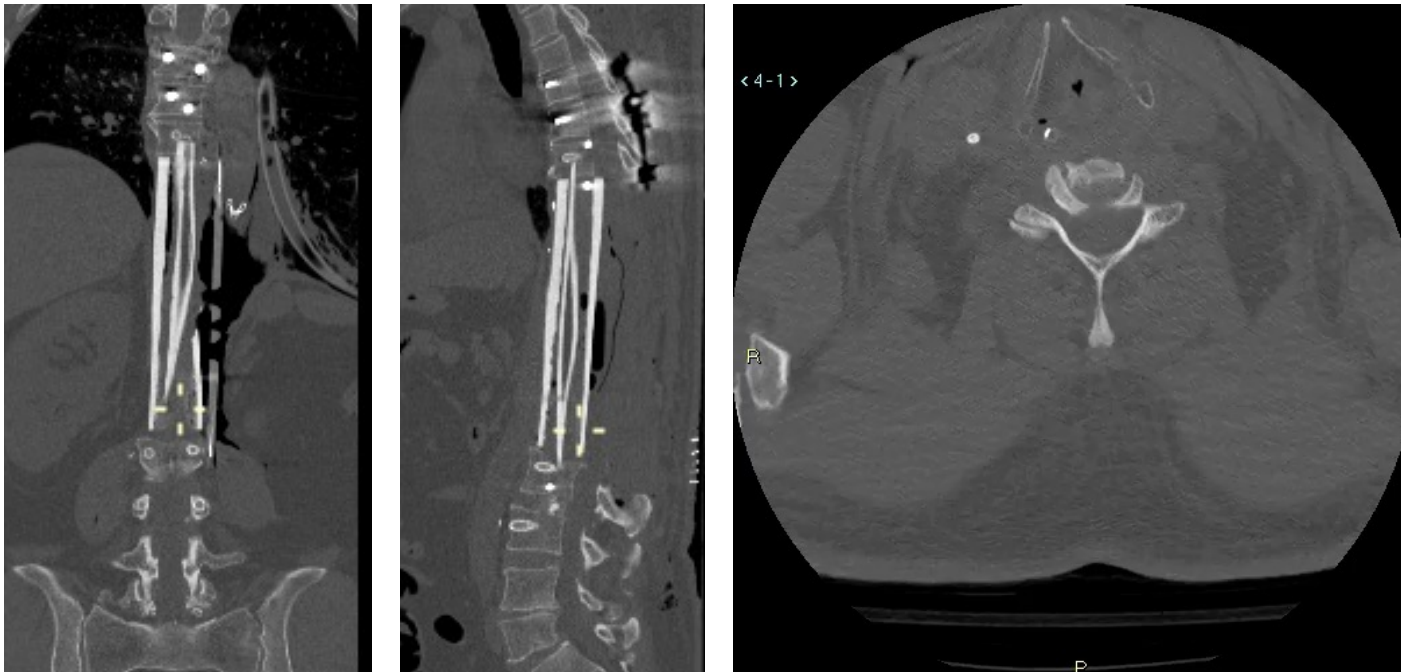P.S.G. 58 yo, male – T8, T9, T10, T11, T12, L1 Chordoma



P.S.G. 58 yo, male – T8, T9, T10, T11, T12, L1 Chordoma



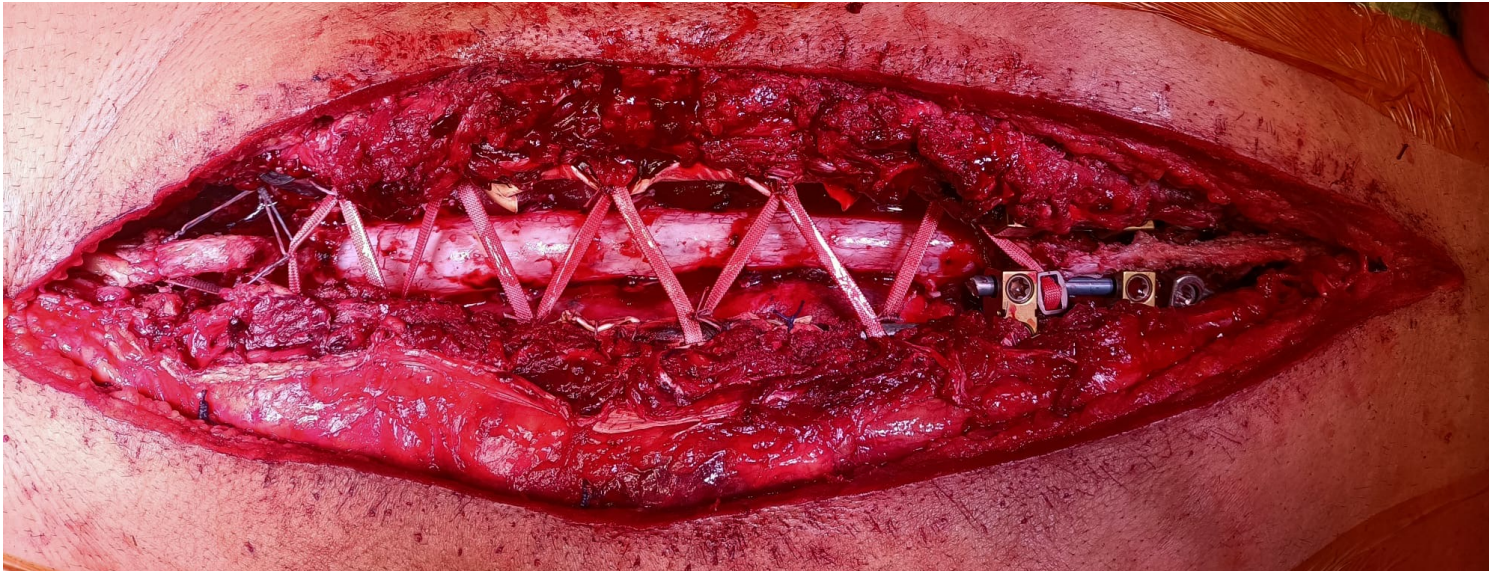P.S.G. 58 yo, male – T8, T9, T10, T11, T12, L1 Chordoma



P.S.G. 58 yo, male – T8, T9, T10, T11, T12, L1 Chordoma

1° gpo: paraplegia

Decompressione dell'ematoma

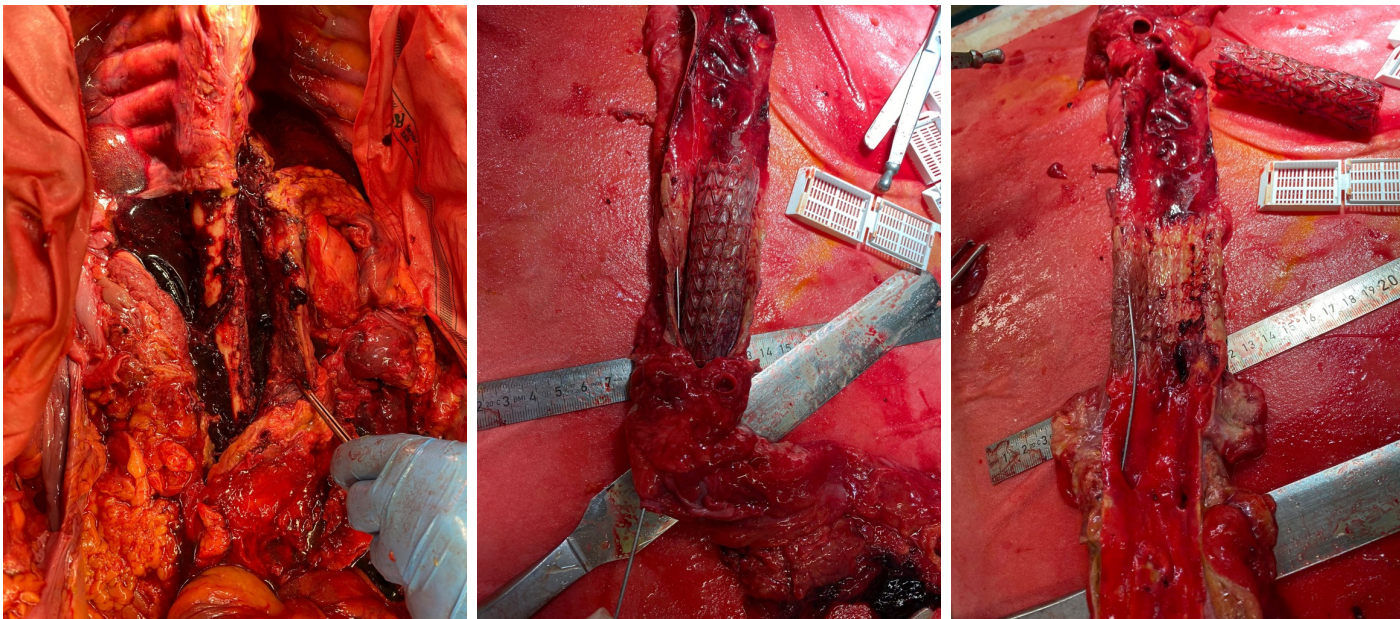


P.S.G. 58 yo, male – T8, T9, T10, T11, T12, L1 Chordoma

Fisioterapia in reparto con progressivo recupero della motilità degli arti inferiori.

15° gpo: addome acuto.

Autopsia: decesso per dissezione aortica



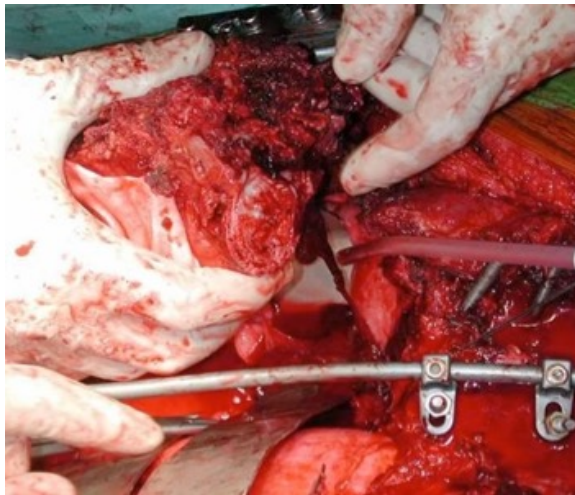
Avremmo potuto evitarlo?

Potevamo essere così efficaci utilizzando una strategia diversa?

Potevamo fare di più?

Avremmo dovuto fare meno?

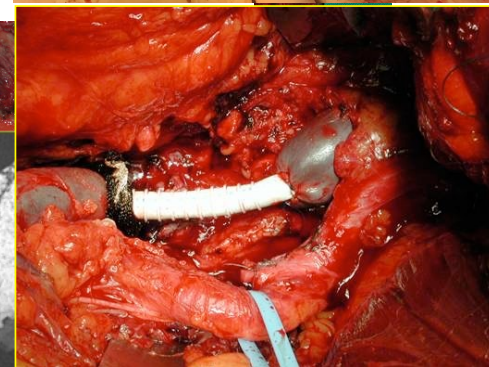
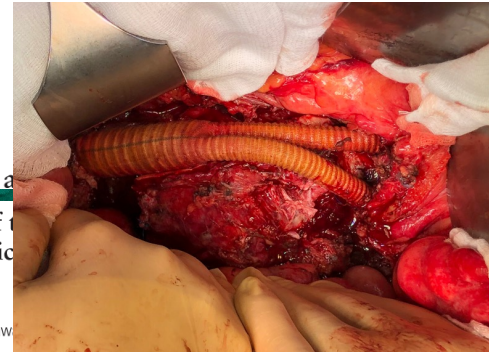
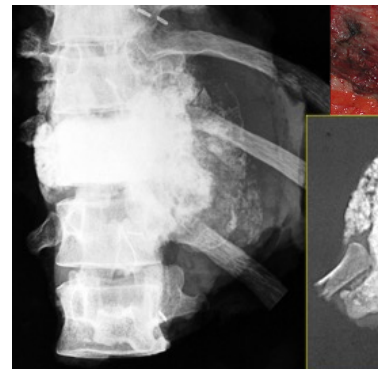Strutture non resecabili?

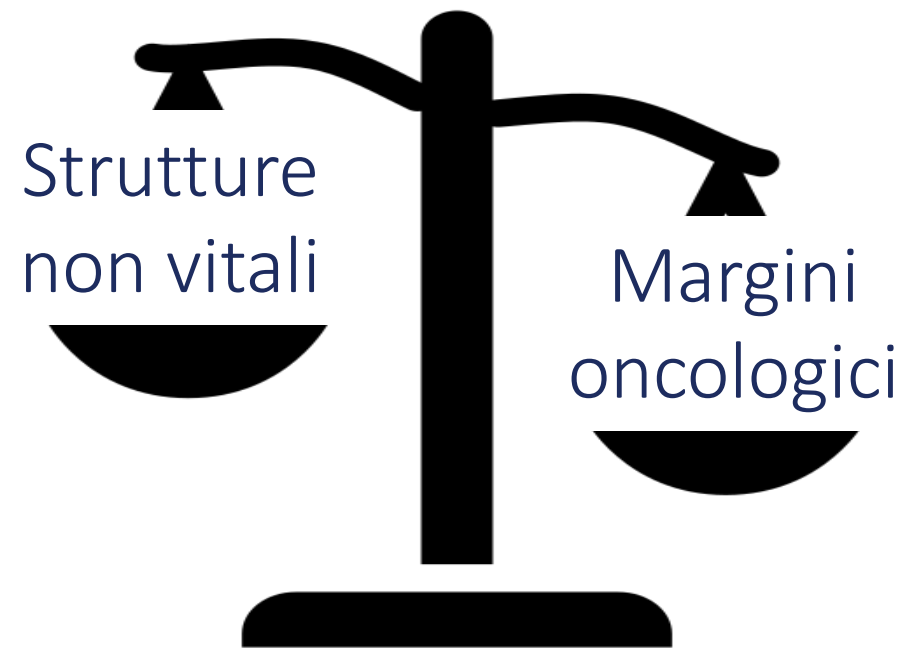


...

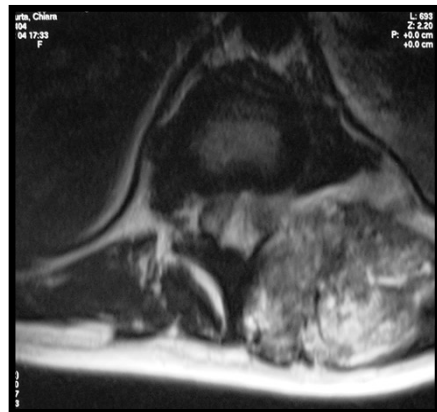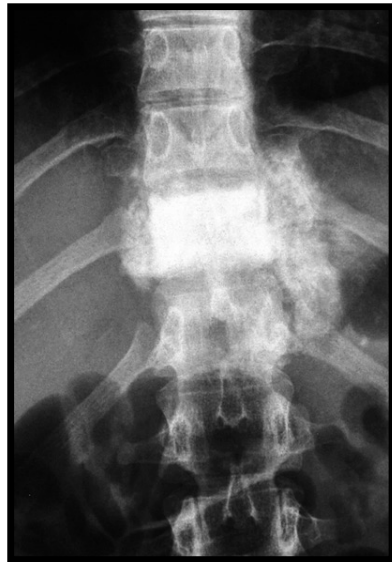■ *En Bloc* Vertebrectomy and ■ Complete Segmental Resection of the Spinal Cord, for Telangiectatic Hemangioma: A Report of 2 Cases

Hideki Murakami, MD,* Katsuro Tomita, MD,* Norio Kawano, MD,*
Tetsutaro Yahata, MD,* and Takehiko Yamaguchi, MD†

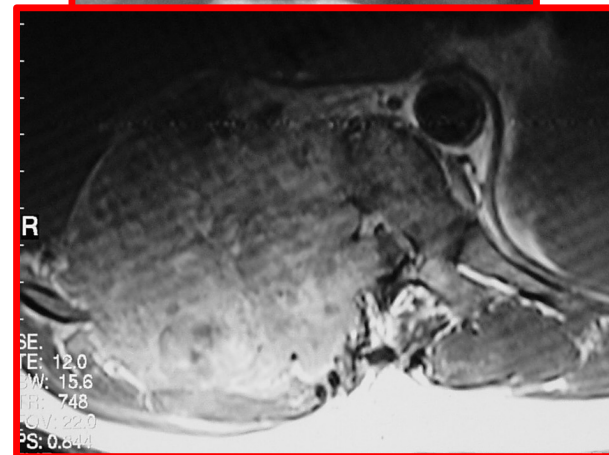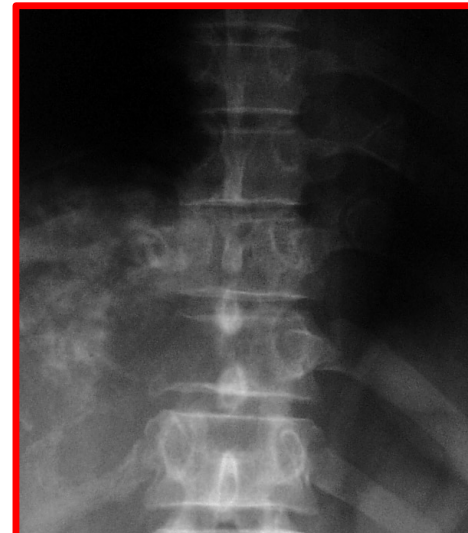




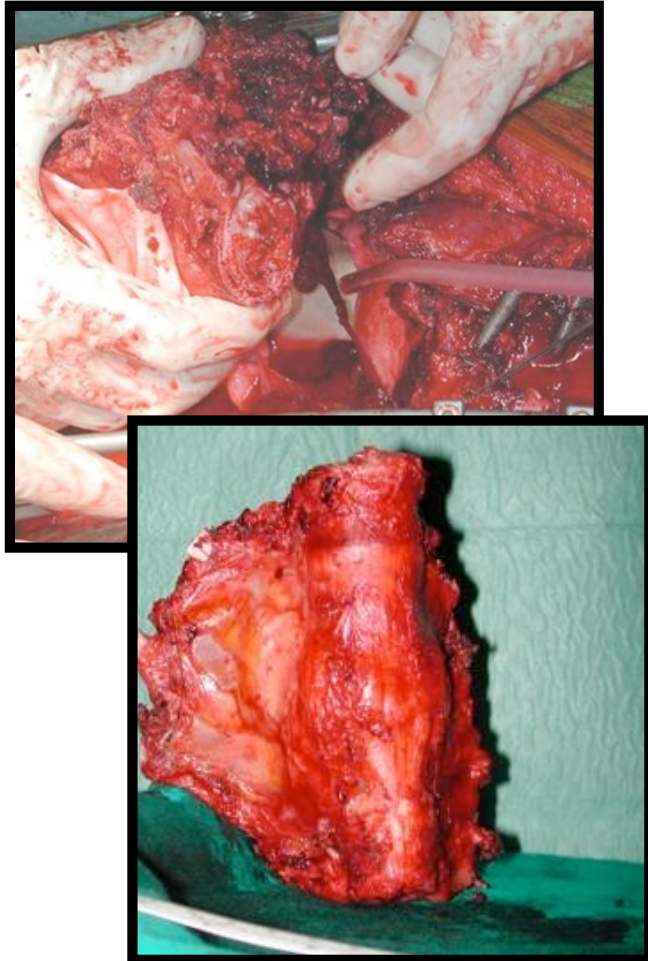
Case 1



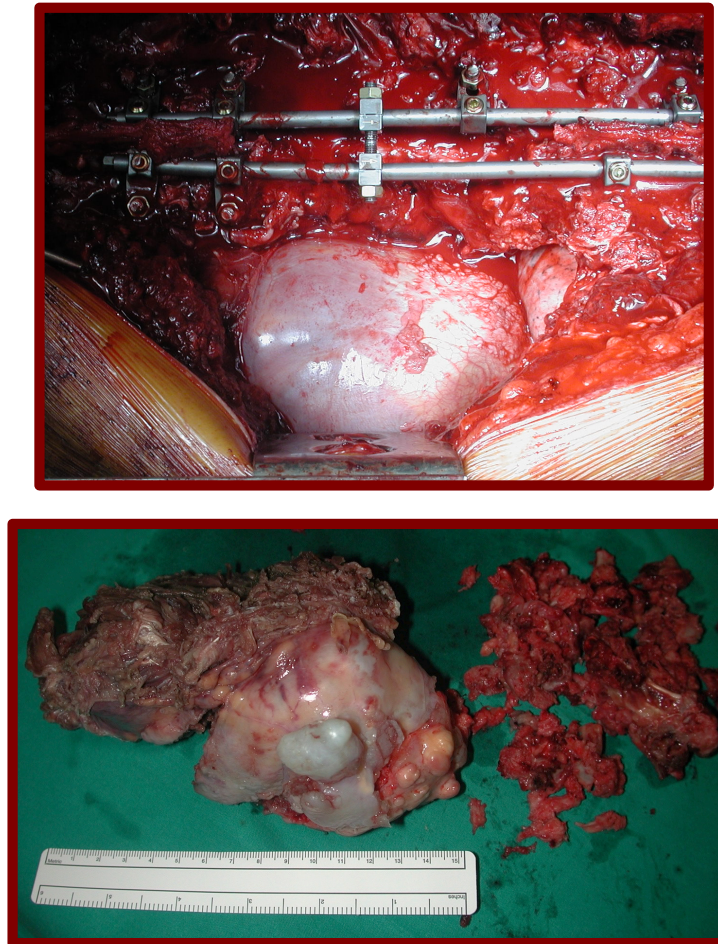
Case 2



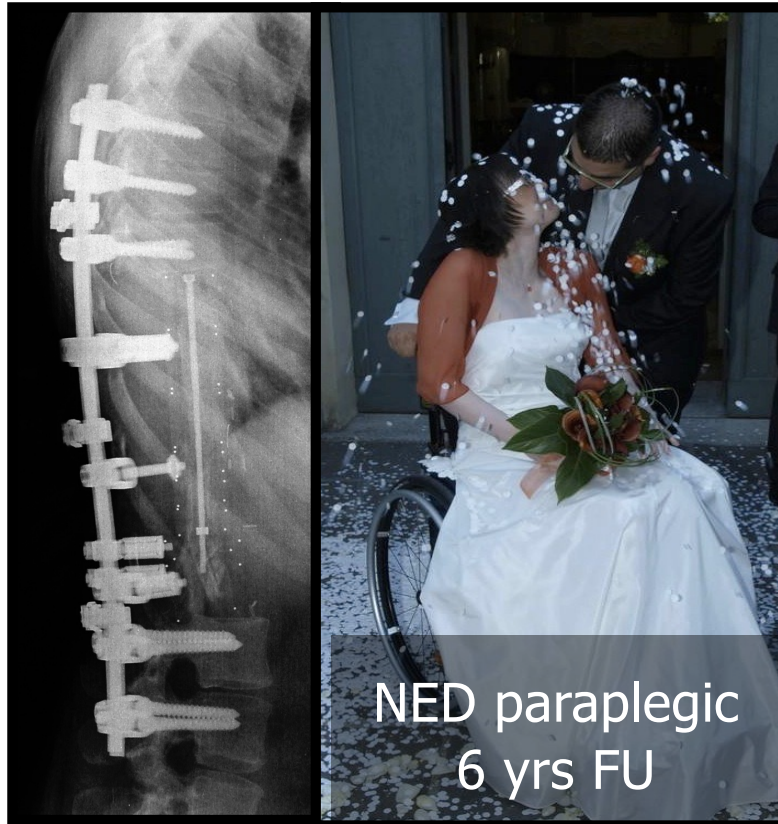Case 1



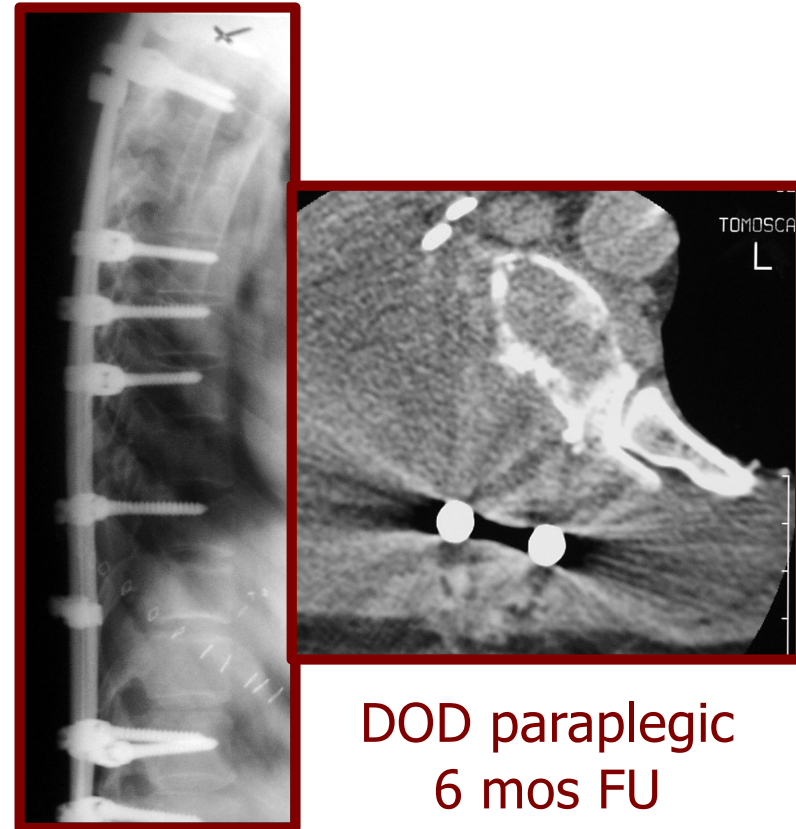
Case 2



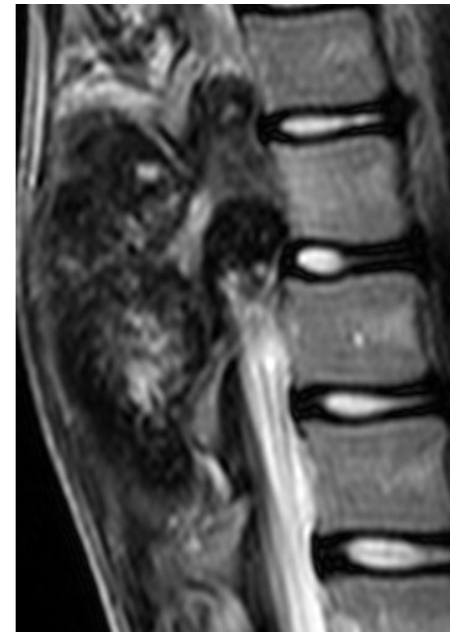
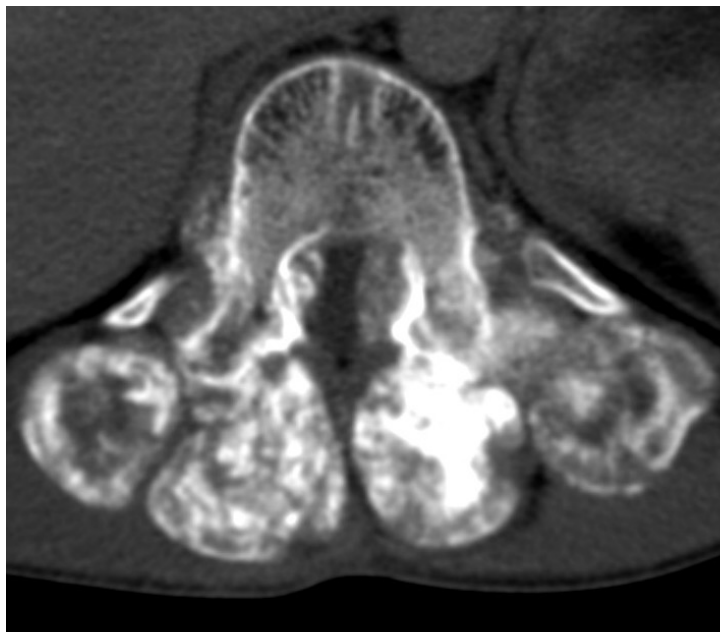
Case 1



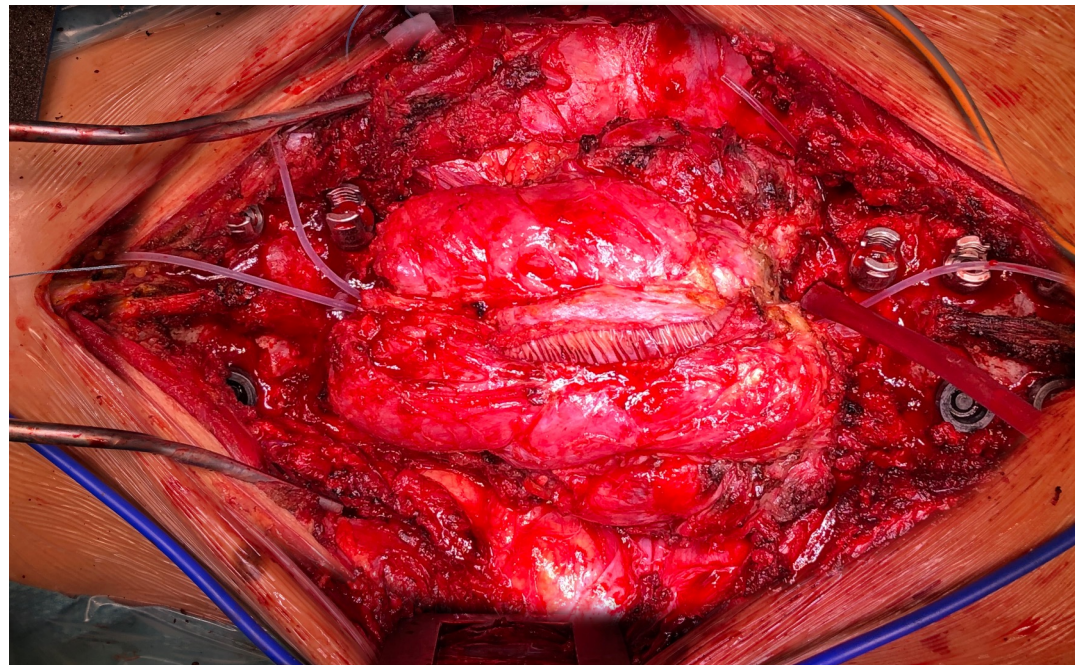Case 2



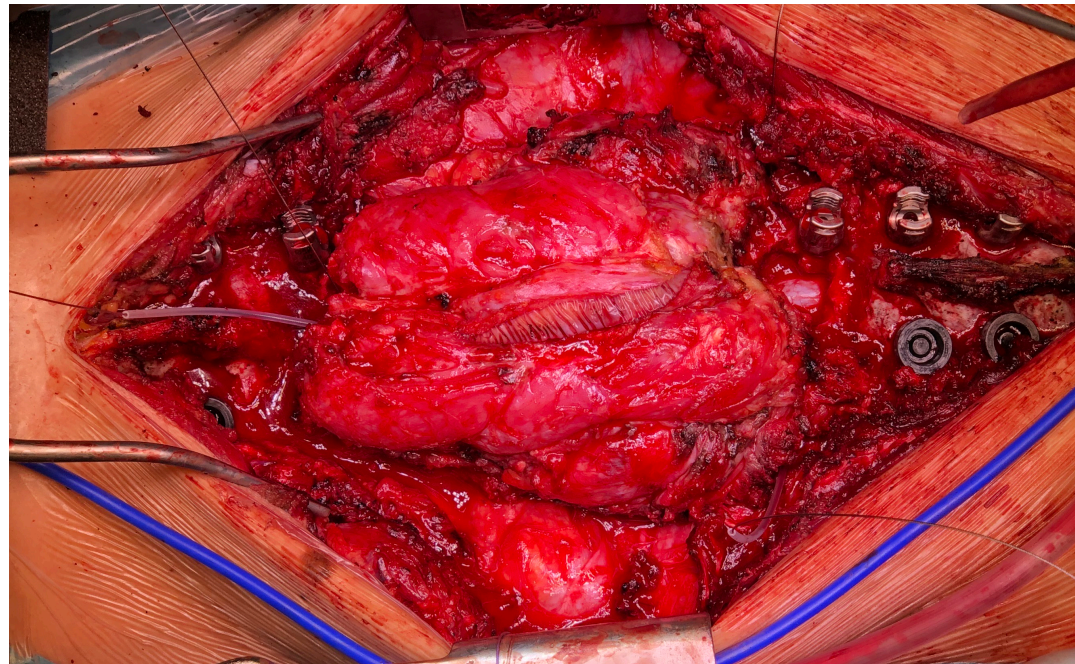
C.D. male, 12 yo – Osteosarcoma T11-L2



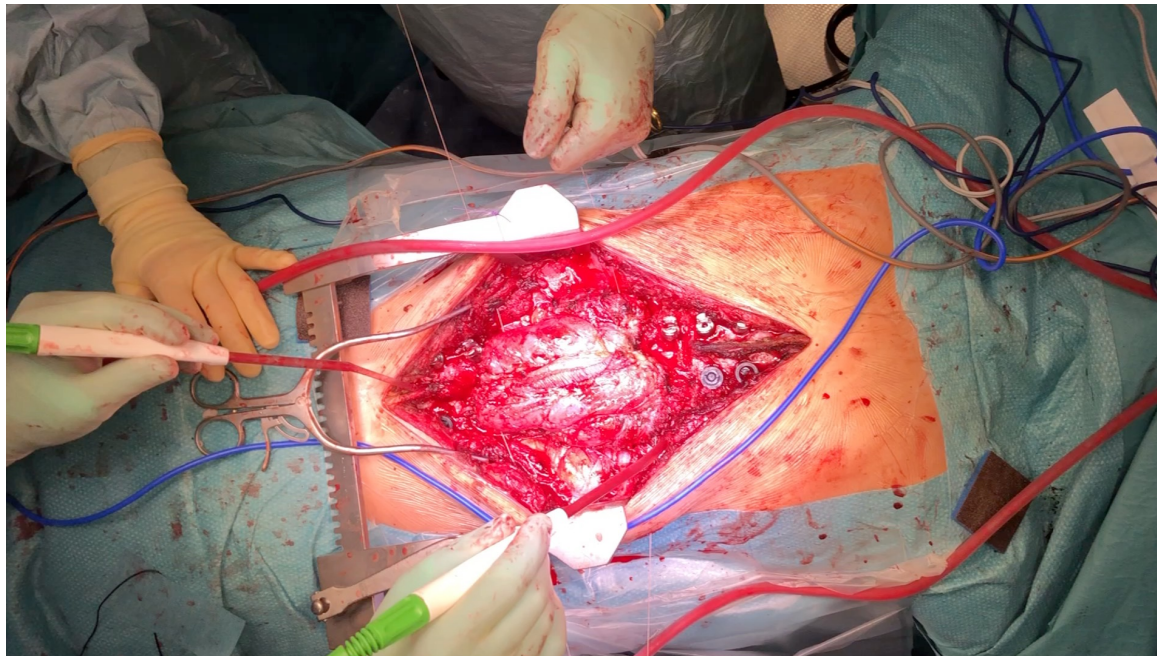
C.D. male, 12 yo – Osteosarcoma T11-L2



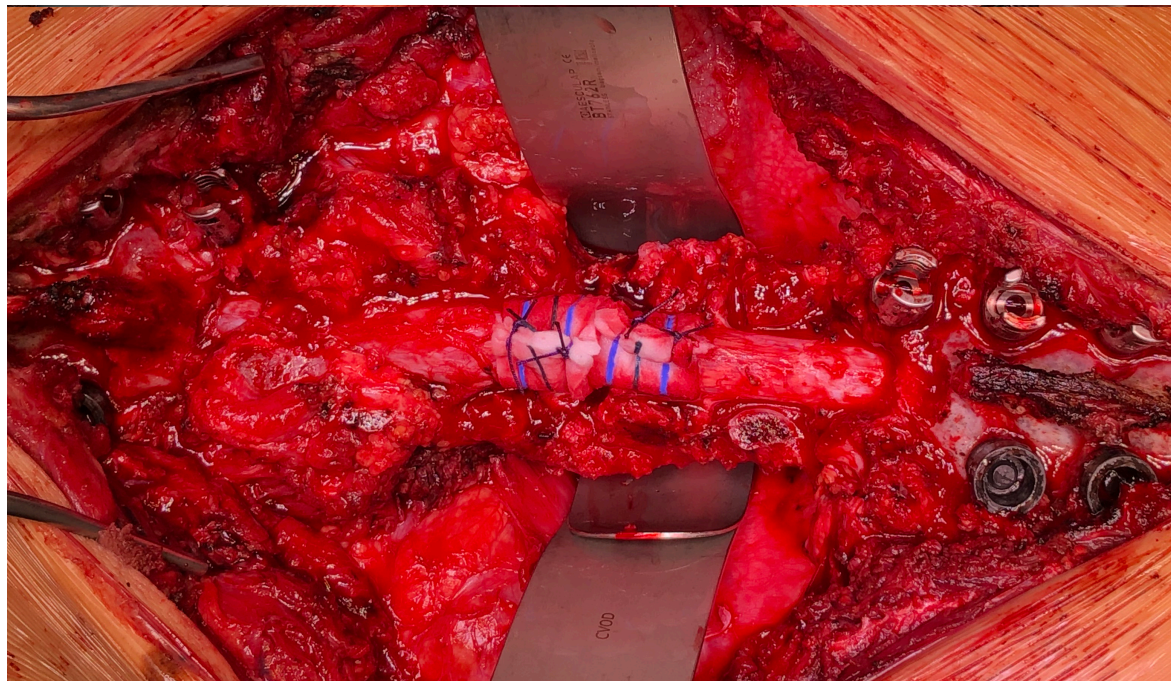
C.D. male, 12 yo – Osteosarcoma T11-L2



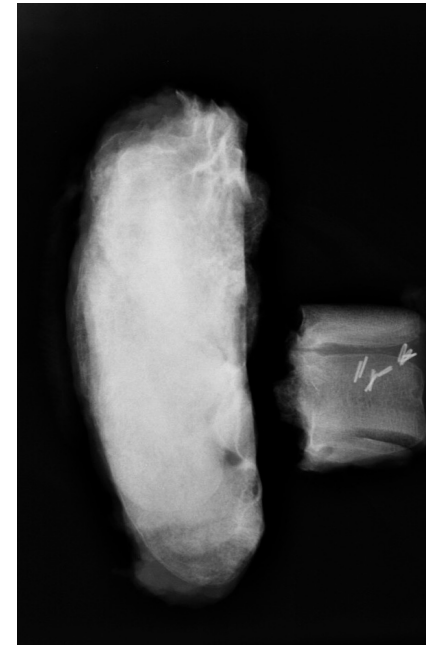
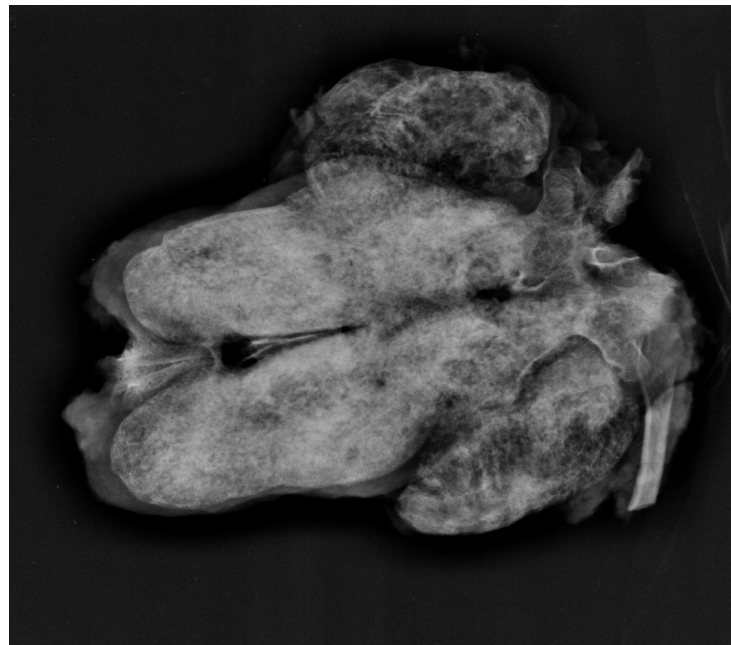
C.D. male, 12 yo – Osteosarcoma T11-L2



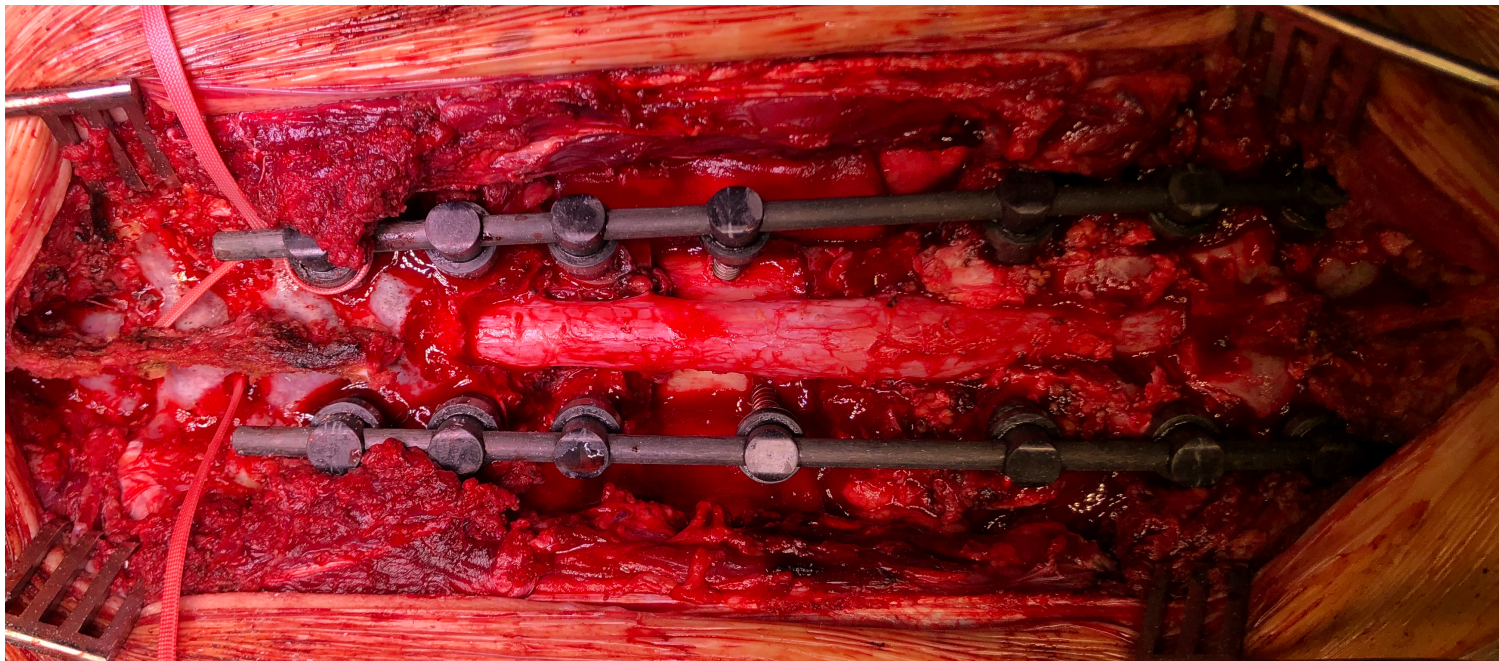
C.D. male, 12 yo – Osteosarcoma T11-L2



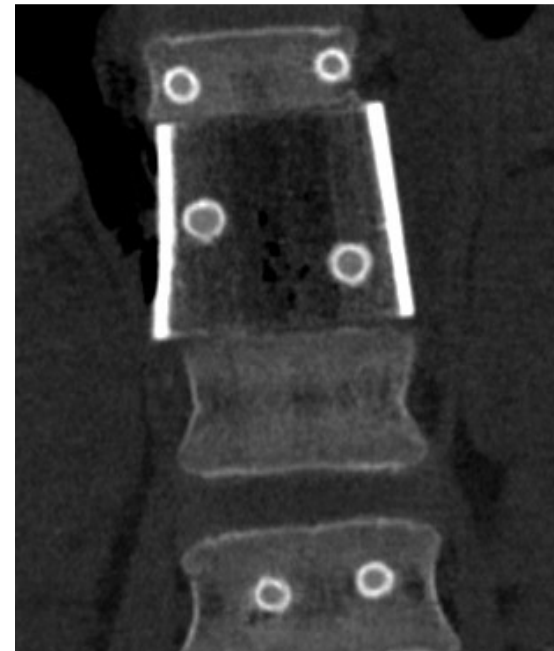
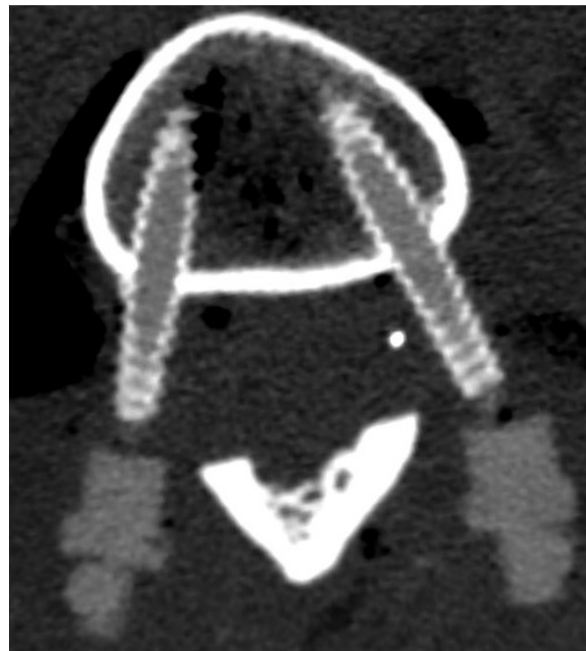
C.D. male, 12 yo – Osteosarcoma T11-L2



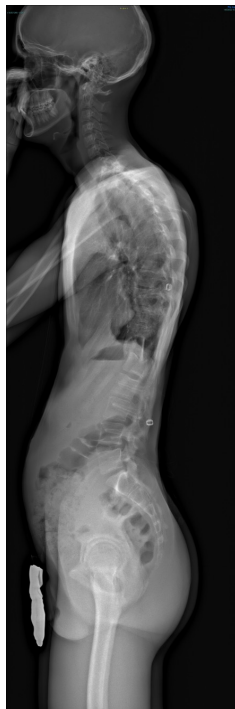C.D. male, 12 yo – Osteosarcoma T11-L2



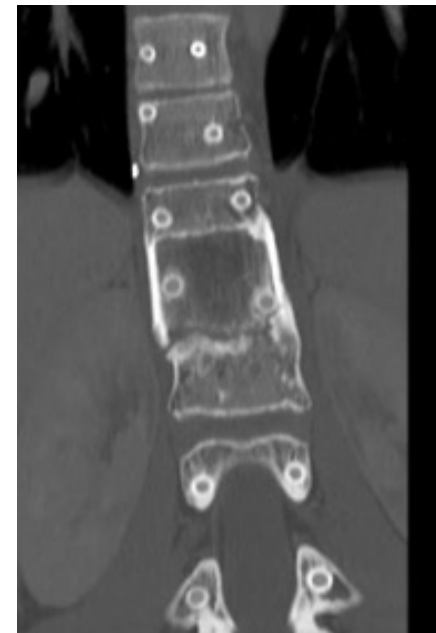
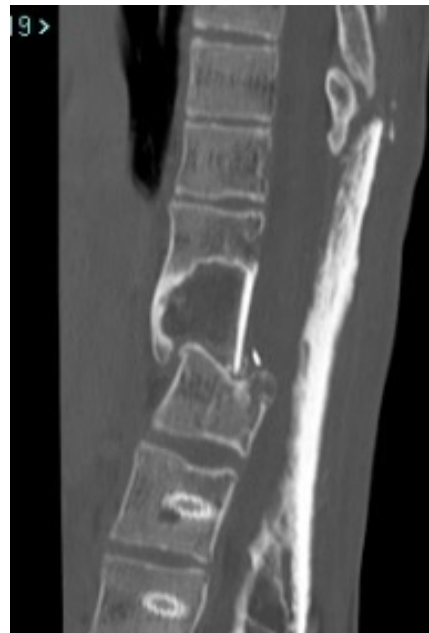
C.D. male, 12 yo – Osteosarcoma T11-L2



C.D. male, 12 yo – Osteosarcoma T11-L2



4 yrs
FU



C.D. male, 12 yo – Osteosarcoma T11-L2



4 anni di FU
2 vertebre resecate
9 livelli stabilizzati

13 sulla canottiera

15 punti

Lunga curva di apprendimento

Concentrare i pazienti in pochi centri specializzati

Approccio multidisciplinare e multispecialistico

Non improvvisare

34° Corso di Aggiornamento in Medicina Fisica e Riabilitativa

